

XXVI. *On the Mechanism of Respiration.* By FRANCIS SIBSON, Esq.
 Communicated by THOMAS BELL, Esq., F.R.S., &c.

Received December 18, 1845,—Read March 12, 1846.

1. SIX or seven years since, while examining the chest in persons subject to dyspnœa, I was struck by observing that the latissimus dorsi and the serratus magnus muscles acted during forcible expiration; on further inquiry, I found that neither of them acted during inspiration. I also ascertained that, on *inspiration*, the scaleni acted during the whole time; that the superior ribs came nearer to each other, and the inferior moved farther apart; and that the internal intercostal muscles between the six superior costal cartilages and the external intercostal muscles between the superior ribs were in action.

I communicated these observations to Professor BELL; he advised me to examine and figure the muscles of respiration in the lower animals. This I did.

After making an extensive series of dissections and illustrations of the respiratory apparatus in the animals that breathe with ribs, I exposed the muscles of respiration in the Dog and the Ass while alive, and observed what muscles acted on inspiration, and what on expiration. I afterwards inflated the lungs in the dead animal, and found that the same muscles that acted during inspiration were shortened when the lungs were distended. This was important, as it rendered the repetition of vivisections less necessary.

Having extended these inquiries to all classes of animals breathing by ribs, commencing with the simplest, and ascending to Man, I came to the conclusion that the mechanical part of the function of respiration was far more complicated than it has generally been regarded, and that in some important particulars the generally received opinions on the subject required to be essentially changed.

This series of researches form the subject of the following paper.

REPTILES, §§ 2–16.

2. The serpent tribe of reptiles, possessing no sternum, have ribs which are connected with the vertebræ only, being without costal cartilages.

SNAKE, §§ 3–11, Plate XXIII. fig. I. *a.b.*

3. In the Snake, the ribs, besides their respiratory action, serve as limbs for progression. The question, What are its respiratory muscles? becomes complicated with another question, What are its muscles of progression? Do the same muscles serve both functions, or is each function performed by distinct muscles?

Lateral muscles of locomotion (30).

It may be affirmed that the numerous many-headed lateral muscles (30.30.30.) which pass from rib to rib, are devoted to locomotion. They, acting on alternate sides, draw the ribs to which they are attached nearer to each other, curve the spine laterally, and spread the ribs of the opposite side farther apart. The other muscles probably serve both for locomotion and respiration.

4. *The ribs are simple.*

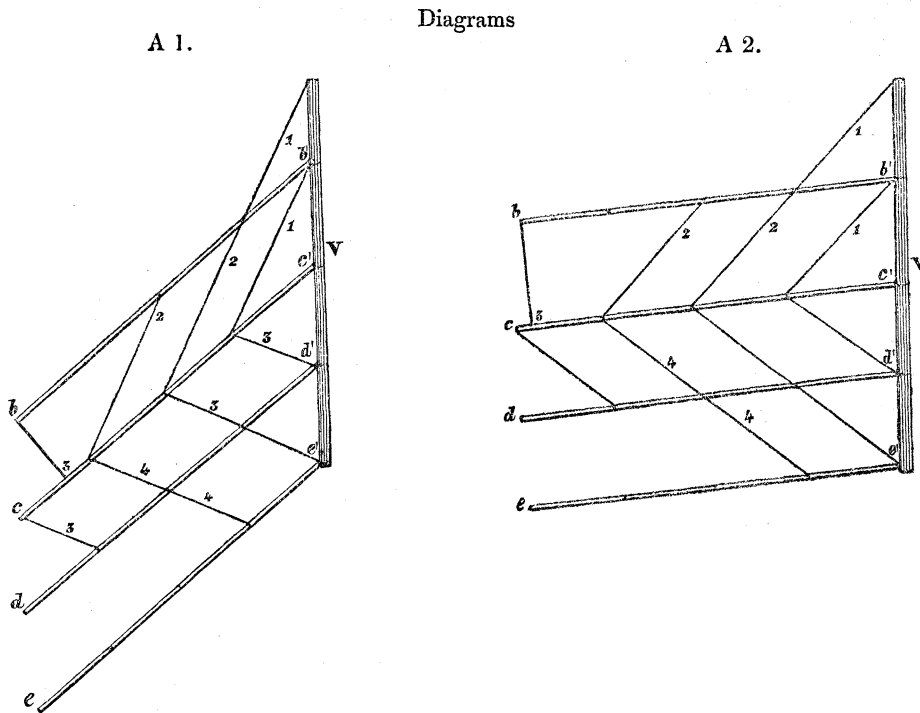
The ribs of the Snake are so simple that their action in breathing is very intelligible. If we distend the lungs to the full, and note how the position of the ribs is changed, what muscles are shortened and what lengthened, we shall ascertain what movements of the ribs will cause an inspiration, what an expiration, and we shall discover what muscles are inspiratory, what expiratory. The shortening of a muscle is conclusive evidence of its action; if we find one set of muscles shortened when we distend the lungs, another set lengthened, we know that the shortened muscles are inspiratory, the lengthened expiratory. I have not ascertained experimentally on the Snake that the same muscles act when the animal inspires that are shortened when we distend the lungs, but I have ascertained it in the Dog and the Ass. I observed these animals breathe when the muscles were exposed, noted the actions of the various muscles one by one, and after death inflated the lungs; those muscles that acted during inspiration were invariably shortened when the lung was distended, and those that were passive were lengthened; on the other hand, those muscles that were active during expiration, were shortened when the lungs were flaccid. This fact rendered it unnecessary to find out by further vivisections the actions of the respiratory muscles, they could be ascertained leisurely on the dead body and represented by accurate drawings; such drawings I have made by aid of the tracing-frame recommended to me by Dr. HODGKIN*. These drawings exhibit the changes effected in the form of the chest, the direction of the ribs, and the length of the various respiratory muscles in inspiration and expiration.

In the Snake all the ribs have similar motions and similar muscles by which the motions are effected.

5. On inspiration, or rather on distending the lungs, for I never noticed a snake inspire, the ribs are raised at their free extremity and throughout their whole course. The range of motion of the free end is greatest, that end being most remote from the centre of the ribs motion at the vertebræ. If we assume that the rib is a straight rod, we can examine the motions of the various ribs in relation to each other uncomplicated by disturbing or diagonal motions.

* This tracing-frame I have described in a paper on the Relative Situation of the Internal Organs, published in the volume for 1844 of the Transactions of the Provincial Medical and Surgical Association. It has been of essential value to me both in this inquiry and in that just referred to.

6. On inspiration; the ribs are raised, move forwards, glide on each other, move farther apart. Diagrams A 1.2.



In diagram A 1 the ribs are depressed at their free ends as in the state of *expiration*.

In diagram A 2 they are raised as in the state of *inspiration*.

V. indicates the spinal column.

b. c. d. e. the ribs, their free ends.

b'. c'. d'. e'. the vertebral ends of the ribs.

When the ribs are raised the free ends move forwards so as to be more distant from the vertebræ; the result is, the chest is deepened. The various ribs b. c. d. e. are more distant from each other in fig. A 1, inspiration, than in fig. A 2, expiration.

In fig. A 1, expiration, the free end of the rib c is considerably in front of a line b.3, drawn at right angles to the rib b. In fig. A 2, inspiration, the free end of c is very little in front of such line b.3; it follows that the lower edge of the superior rib b glides forward in relation to the upper edge of the inferior rib c; and *vice versa*, the upper edge of the lower rib c glides backwards in relation to the lower edge of the upper rib b.

7. The levatores costarum and external intercostals are inspiratory. Diagram A 2.

It is evident that the line 1 representing the levator costæ is much shorter in diagram A 2, inspiration, than in diagram A 1, expiration; it is also evident that the lines 2.2.2 representing the external intercostals, which descend obliquely forwards,

are much shorter in diagram 2, inspiration, than in diagram 1, expiration. It follows that the external intercostals are inspiratory.

The rib is raised by the levator costæ and by the external intercostal, and the upper edge of the lower rib is made to glide backwards in relation to the lower edge of the upper rib by the external intercostal, whose fibres, passing downwards and forwards, necessarily pull the lower rib upwards and backwards.

8. *The internal intercostals are expiratory. Diagram A 1.*

The line 3, representing the internal intercostal, whose fibres pass obliquely upwards and forwards, is much shorter in diagram A 1, expiration, than in diagram A 2, inspiration. It follows that this muscle is expiratory. The internal intercostal is expiratory, it lowers the upper rib, and causes its lower edge to glide backwards in relation to the upper edge of the lower rib.

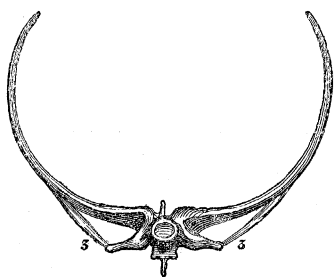
The line 4.4 represents a muscle in the Snake that passes over one rib to be inserted into the next rib but one above; it has the same action as the internal intercostals.

9. *On inspiration the ribs are drawn backwards posteriorly, outwards laterally, and move forwards anteriorly. Diagrams B 1.2.*

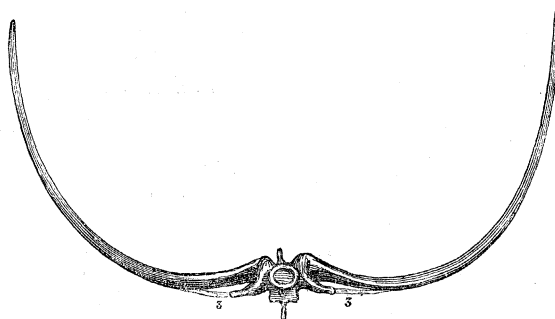
Besides the elevation of the rib during inspiration each rib is drawn backwards, so as to increase the area between the ribs of the two sides.

The levator costæ draws the rib backwards, B 2.

Diagram B 1.



B 2.



The ribs are drawn thus backwards by the levatores costarum, 3.3, the origin of which is behind the centre of motion of the rib at its articulation with the vertebra. The levator costæ (3) is shorter in diagram B 2, inspiration, than in diagram B 1, expiration.

The backward motion of the ribs during inspiration (B 2) counterbalances to a great extent the forward motion of their free ends, due to their inspiratory elevation, diagram A 2. § 6.

It follows that during inspiration the vertebral and lateral portions of the rib move

backwards and outwards, while the free end moves forward; thus the space between the ribs is deepened and widened at the same time.

During expiration the ribs are lowered, their free ends move downwards, inwards and backwards; while the lateral and vertebral portions move downwards, inwards and forwards; thus the area between the ribs is narrowed and made less deep.

10. *Inspiratory muscles; scaleni* (fig. I. 1); *levatores costarum* (fig. I. 6); *external intercostals* (fig. I. 7); &c.

The inspiratory muscles in the Snake are the scaleni (1), descending from the cervical vertebræ to the first ribs, and by continuation to the succeeding ribs. The continuous fibres are parallel to and blended with those of the external intercostal muscles.

The external intercostal muscles (7) are shorter in fig. I. *e*, inspiration, than in fig. I. *d*, expiration. There are several other inspiratory muscles. Two of these (32.34) arise from the vertebra and are inserted into the rib, below and in front of the levator costæ, another (33) passes from rib to rib near the vertebræ; these are probably chiefly muscles of progression; they are all shortened when the lungs are expanded and the ribs are raised.

11. *Expiratory muscles; depressors of the ribs* (fig. I. 31); *internal intercostals* (fig. I. 21) (*pass within one rib*); *transversalis* (fig. I. 20).

The expiratory muscles.—A series of narrow, ribbon-like muscles (31), peculiar to the serpent tribe, lies in front of the vertebral portions of the ribs; each of these muscles takes its rise from the body of the vertebra, ascends obliquely outwards and passes in front of four or five ribs to be inserted into the lower edge of the fifth or sixth rib above. These muscles are attached about half-way between the vertebræ and the free ends of the ribs, and are much shortened when the lungs are flaccid. They pull the ribs downwards, and narrow the chest between the opposite ribs by drawing them nearer to each other, and by bringing forward their vertebral portion. They antagonize the levatores costarum.

A muscle (21) arises from the upper edge of the rib just above the insertion of the depressor of the rib, this passes obliquely upwards and outwards in front of one rib, to be inserted into the lower edge of the second rib above, near to its free end. This is shorter when the lung is flaccid than when it is distended, and is in fact a continuation of the depressor of the rib, the rib being interposed; it represents the internal intercostal.

A transversalis muscle (20) forms a musculo-tendinous web over the whole belly; it is attached to the inner surface of the rib where the depressor costæ is inserted, and acts with the depressor costæ to narrow the area between the opposed ribs.

There are cutaneous muscles that assist in expiration in front of the transversalis, which are connected with the ribs externally.

THE CHAMELEON, §§ 12-16, Plate XXIII. fig. II.

12. The Chameleon, though a cold-blooded animal, whose movements are for the most part sluggish, and whose breathing is slow and irregular, yet stands in need of occasional very deep inspirations and very sudden and complete expirations.

13. *Has a sternum, and long costal cartilages in addition to the ribs.*

The Chameleon has a greater portion of rib movement than almost any other four-legged creature. The ribs, which are long and slender, yet strong, are eighteen in number; the lowest rib is at a very short distance from the pelvis. The first and second ribs have no cartilages; the rest, excepting the last, have long, firm, slender cartilages, attached by very flexible almost tendinous intermedia to the ends of the ribs. The costal cartilages of the third, fourth and fifth ribs, are attached to the sternum. They resemble closely the costo-sternal ribs of birds. The remainder have their anterior extremities free.

The addition of a complete system of anterior ribs or moveable cartilages gives the Chameleon a double power over the Snake for the expansion of its lungs. I defer considering the mode in which the anterior ribs act in expanding and narrowing the chest, until I describe the mechanism of breathing in birds, as it is so much more intelligible and explicable in the Bird than in the Chameleon.

14. *Inspiratory muscles acting on the ribs, Plate XXIII. fig. II. 1.5.6.7.*

The scalenus (1), the levatores costarum (5.6), and the external intercostals (7), have the same action and nearly the same anatomical distribution that they have in the Snake. They combine to elevate the ribs, push forwards their anterior ends, and draw backwards their posterior curves; they thus deepen and widen the chest. The fibres of the external intercostal muscles between the first and second, and second and third ribs, have the same direction with those of the scalenus, of which indeed they seem to be a continuation, the ribs being interposed.

In addition to these muscles, there is between some of the ribs another external intercostal (7), whose fibres are superficial to, and less oblique than the usual external intercostal.

15. *Inspiratory muscles of the cartilages, Plate XXIII. fig. II. 9.*

The first costal cartilage is raised by a strong triangular muscle arising from the sternum (9); strong muscular fibres pass from the first cartilage to the second, and raise it on inspiration; the rest have between them webs of aponeurotic tissue.

16. *Expiratory muscles, Plate XXIII. fig. II. 31.21.32.30.19.17.*

In expiration a series of small muscles (31) lower the ribs; each arises from the vertebra to be inserted into the lower edge of the rib above.

A set of muscles (21), as in the Snake, arise from the upper edge of one rib, and pass upwards over the inner surface of another, to be inserted into the rib but one above. An internal intercostal (21) arises from the upper edge of that portion of the rib into the lower edge of which the last muscle is inserted. This muscle is inserted into the anterior portion of the rib above. The Chameleon has peculiar to it a muscle to narrow the chest, by drawing the ribs inwards and nearer to those of the opposite side. This muscle (32) arises from the body of the vertebra anterior to the articulation of the rib, and is inserted into the inner surface of the rib near the vertebral head.

A long external depressor of the ribs (*longissimus dorsi*, 30) arises from the pelvis, and is inserted by many tendons into the lower edges of the ribs.

The chest is narrowed anteriorly by the transversales muscles (19.19) that arise from the anterior end of the vertebral ribs, and are inserted, the upper portion into the sternum, the rest into the costal cartilages; they cause the cartilages to bend on the ribs in expiration.

The ribs are lowered by an external oblique (17).

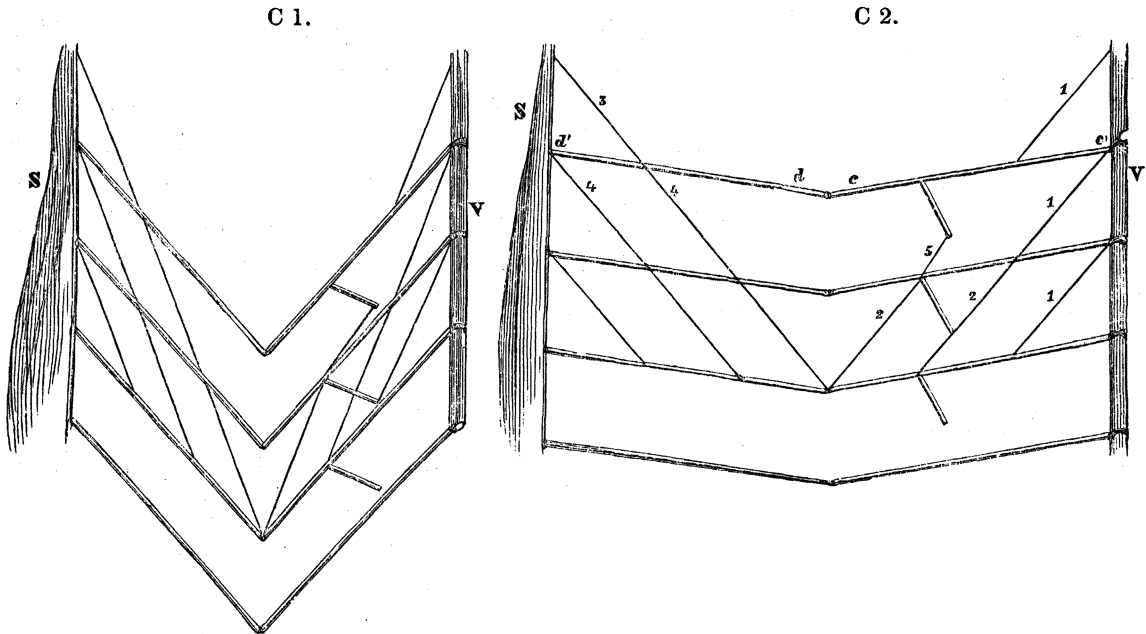
BIRDS, §§ 17–27 (Plate XXIV. fig. III. *a.b.c*, Plate XXV. figs. IV. V. VI. *a.b*).

17. *Birds have, in addition to spinal ribs, a sternum and sternal ribs.*

Birds have a complete apparatus of ribs hinging on the sternum, in addition to, and articulated with, those hinging on the vertebral column. The vertebræ and the vertebral ribs combine with the sternum and the sternal ribs to complete a circuit, forming, as it were, a cylinder or cavity enclosing and protecting the lungs, heart, and abdominal viscera. In such a manner do they combine and articulate that, by the movements of the ribs, the cavity can be enlarged on inspiration and lessened on expiration. The sternum bears the same relation to the sternal ribs that the vertebral column does to the vertebral ribs. These sternal ribs are long slender bones that articulate at one extremity with the sternum, at the other with the vertebral ribs.

18. *Diagram C 1.2. On inspiration, the sternal as well as the spinal ribs are raised, glide on each other (§ 6, 7) and move farther apart.*

Diagram C 1 represents the vertebral and sternal ribs in the position they have in expiration; diagram C 2, that they take up in inspiration. It is here, as in diagram A 1.2, inferred that the ribs, both sternal and vertebral, are all straight rods of equal length, hinging on the vertebræ V and sternum S with upward and downward motions.



While the obliquity of the vertebral ribs is from behind forwards and downwards, that of the sternal ribs is from before backwards and downwards. The motions of the sternal ribs on the sternum are precisely the same in principle with the motions of the vertebral ribs on the vertebræ, only they are all reversed. While the distant ends of the latter ribs when raised move forwards from the vertebræ, those of the former move backwards from the sternum; while the upper edge of each vertebral rib glides backwards in relation to the lower edge of the rib above (§ 6, 7), that of the sternal rib glides forwards.

The same holds as to the muscles; while the scalenus or levator costæ (1) raises the vertebral rib, the sterno-costalis (3) elevates the first sternal rib; while the external intercostals (2) elevate and give the gliding motion to the vertebral ribs (§ 6, 7), the sternal intercostals (4) give the same motions to the sternal ribs; and while the muscles of the vertebral ribs are directed forwards and downwards, those of the sternal ribs pass backwards and downwards. The two sets of muscles combine in one action to raise the ends by which the two sets of ribs articulate with each other (§ 6, 7).

19. *On inspiration, the angles formed by the ribs are more open, the sternum and spinal column more distant.*

In diagram C 2, inspiration, the angle *d.c* formed by the articulation of the two ribs is much more open than in diagram C 1, expiration; in the latter they are bent to a right angle, in the former they are nearly straight. As the costal ends of the ribs are more distant from the sternum and vertebræ in inspiration C 2 than in expiration C 1, so, to a double extent, is the distance increased between the sternum and the spinal column; if the spinal column be fixed, the sternum moves forwards to a very great extent.

20. *Spinal ribs.*

All the spinal ribs, except the two first, which have free anterior extremities, articulate with sternal ribs. Those ribs that articulate with the vertebræ, and likewise with costal ribs, are of about equal length, and have spurs from their lower edges to give attachment and purchase to various muscles. The lowest ribs articulate with the pelvis. The pelvic ribs have no spurs, are longer than the purely vertebral ribs, and usually articulate with sternal ribs that are joined to each other near the sternum, with which they have a common articulation.

Each purely vertebral rib has two articulations, one with the body, the other with the transverse process of the vertebra; this last attachment allows the rib to be raised, but prevents that free range of forward motion that is permitted in the Snake.

21. *Sternal ribs.*

The superior sternal ribs are very short, many times shorter than the corresponding vertebral ribs; they become gradually longer, the lowest equalling in length the corresponding vertebral ribs.

22. I have watched the motions of the chest in the living fowl, and observed the action of a few of the muscles by vivisection. Figs. VI. *a. b.* Plate XXV. represents the Swan; in fig. VI. *a.* the chest is contracted; in fig. VI. *b.* expanded. I could not distend the lung owing to the air-sacs; but I imitated inspiration exactly by drawing the sternum further from the vertebræ. It will be seen from these diagrams that the elevation of the ribs pushes forward the lower part of the sternum much further from the spine than the upper. This is owing to the lower sternal ribs being much longer, and having therefore a much greater range of motion than the upper.

23. *Inspiratory muscles of the spinal ribs.* *Scalenus* (1), *levator costarum* (2), *external intercostals* (7). Plates XXIV. XXV.

The scalenus (1) is prolonged from the first to the second rib; it corresponds exactly with the levatores costarum (2), which muscles both elevate the ribs and expand the chest. The inferior levators are smaller than the superior, the range of their action being more limited.

The external intercostals (7) are throughout shortened in fig. VI. *b.* inspiration. A portion of the muscle, with fibres almost horizontal, arises from the spur, and shows beautifully the mode in which the muscle acts to draw the upper edge of the lower rib backwards, in relation to the lower edge of the upper rib; in fig. VI. *b.* inspiration, the great shortening of these fibres is well seen.

24. *Inspiratory muscles of the sternal ribs; sterno-costal* (9 *a*); *sternal intercostals* (9).

The superior sternal ribs are raised by the sterno-costal muscle (fig. VI. 9 *a.*), which corresponds with the scalenus; it arises from the upper part of the sternum,

and descends to be inserted into the upper edge of the four or five superior costal ribs ; the bellies to the respective ribs lie behind each other in laminæ : this muscle is much shorter in fig. VI. *b*, inspiration, than in fig. VI. *a*, expiration, as is another muscle arising from the coracoid and inserted into the three first sternal ribs. The fibres of the sternal intercostal muscles (9) are much shorter in fig. VI. *b*, inspiration, than in fig. VI. *a*, expiration ; they, with the sterno-costal muscle, elevate the sternal ribs and make them glide on each other. The combined actions of the scaleni, the levatores costarum, the sterno-costal muscle, the external intercostals, and the sternal intercostals raise the ribs, and push the sternum forwards, the vertebræ slightly backwards.

25. *Inspiratory muscles arising from the scapula*, Plate XXIV. fig. III. *a*. 31.32.29.

I observed the three scapular muscles (31. 32 and 29) to act during inspiration ; 31 and 32 evidently raise the ribs, acting from the scapula ; 29 acts from the ribs on the scapula to elevate it, thus lifting it away from the expanding chest.

26. *Expiratory muscles ; internal oblique* (18) ; *external oblique* (17) ; *rectus* (16) ; *transversalis* (20) ; *internal intercostals* (21 and 19 *a*. figs. III. VI.).

The antagonist muscles to the dilators of the chest are numerous. The internal oblique (18) and the internal intercostal muscles (21), with a muscle (30) acting from the pelvis, combine to draw down the spinal ribs, and to cause the lower edges of the upper ribs to glide backwards on the upper edges of the lower ribs. The external oblique (17), inserted into the spurs, draws the spinal ribs downwards, brings them nearer the sternum, and increases the bend of the sternal on the spinal ribs. The rectus (16) pulls the sternum with the sternal ribs downwards ; the transversalis (20) draws them backwards. In the Fowl the upper part of the sternum is drawn nearer the spine, and the three superior ribs are depressed (the third rib owing to its peculiar curve) by muscles (19 *a*.) stretching from the sternum to the ribs.

27. The lungs and the costal walls are more developed in the Stormy Petrel (fig. V.) than in any other bird I have figured ; the Swan (fig. VI.) ranks next in costal development, then the Hawk (fig. IV.), and lowest of all the Fowl (fig. III.). The development of the lungs and of the costal mechanism evidently depends on the power to sustain flight, to swim, to dive, or to act energetically. The Fowl, which scarcely flies, requires comparatively little lung ; its alimentary canal is protected by an enormous prolongation downwards of the sternum, a very trifling portion of which serves for the costal articulations.

MAMMALIA (*not including Man*), Plate XXVI. figs. VII. VIII., Plate XXVII. figs. IX. X., Plate XXVIII. figs. XI. XII.

28. The chest is expanded in the Mammalia, as in Birds, by the varying position of the ribs ; the principle on which the lungs are dilated in the two classes is the same ; but there are many important modifications.

29. The lungs in birds are imbedded in the spaces between the ribs; they only have a free surface invested with pleura anteriorly. The diaphragm in the Fowl forms with this free surface of the lung an enclosed cavity.

In Mammalia each lung is enclosed in a distinct pleural sac, the whole lung being free, save where the air-tubes and great vessels are attached. This cavity is completely closed above, protected by ribs, muscles and fasciæ. The first rib is more intimately connected than any other with the sternum; in the majority of animals it either directly articulates with that bone, or is united to it by a short firm cartilage. It is in the expansion in every direction of the upper part of the chest, and the great range of descent of the whole diaphragm, the progressive lengthening of the ribs, the arched and comparatively mobile spinal column, and the usually small, jointed sternum, that the mechanism of breathing in the Mammalia chiefly differs from that in Birds; for in Birds the upper part of the chest is not closed in, the diaphragm has but a limited range of motion, the spinal ribs are nearly of a length, the spinal column is stiff, and the sternum is in one large piece.

30. *The costal cartilages of Mammalia are analogous to the sternal ribs of Birds.*

In the Porpoise (Plate XXVI. fig. VII.) a series of bone-like stiff costal cartilages articulate by distinct joints with the sternum and the six superior vertebral ribs. The Sheep, the Cow (Plate XXVII. fig. IX.), and the Pig have costal cartilages that articulate by joints with the ribs and the sternum. These cartilages are every way analogous to the sternal ribs of Birds; they differ merely in this, they are made not of bone, but of cartilage.

31. *Dorsal arch; the ribs are longest at the centre of the arch, and gradually shorten above and below.*

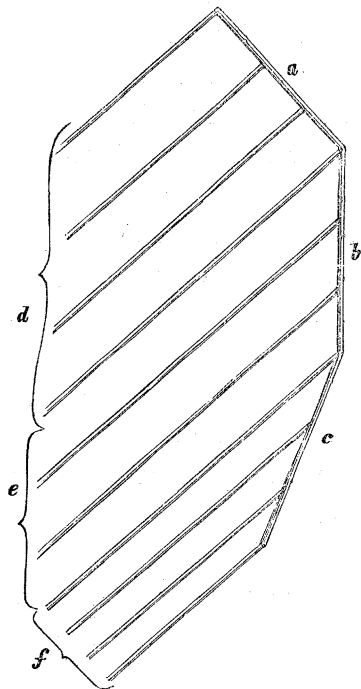
In all animals the lower part of the sternum is more distant from the vertebræ than the upper. The increase in length of the ribs and in depth of the chest takes place gradually from above downwards. The first rib is the shortest, the rest of the ribs increase gradually until about the sixth or seventh, which are the longest and are usually alike in length to each other and to the few following ribs; the three or four lower ribs gradually shorten, the lowest of them being the shortest. The dorsal vertebræ form an arch, the curves of which correspond with the varying length of the ribs. The superior curve of the dorsal vertebræ coincides with the gradual lengthening, and the inferior curve with the gradual shortening of the corresponding ribs.

32. *Influence of the dorsal curves on the movements of the ribs. The upper ribs approach to, the lower recede from one another.*

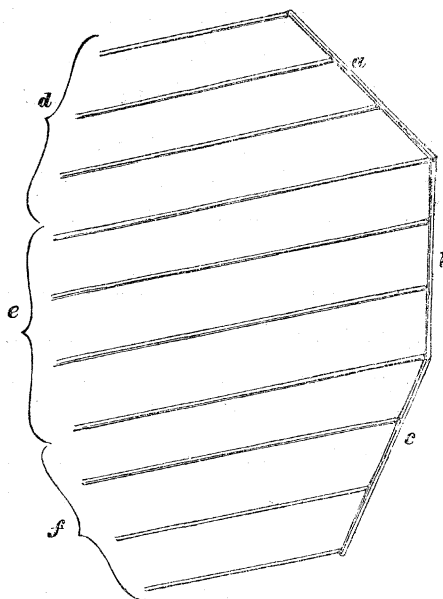
The following diagrams (D 1, D 2) represent in an exaggerated mode, the curves in the dorsal spine, and the changes in position of the ribs when raised, as modified by

the varying curve. *a, b, c* denotes the spinal column; *d, e, f* the ribs represented as straight rods; when the superior ribs *d*, articulating with the upper obliquity *a*, are raised as in D 2, inspiration, they approach each other. When those (*e*) hinging on the vertical portion of the spine are raised, they become more remote; and still more distant do those (*f*) become that articulate with the lower obliquity.

D 1. Expiration.



D 2. Inspiration.



This diagram is overdrawn and does not take into account the curved form of the ribs, their lateral thrust, the extent to which their vertebral portions are drawn backwards, the deepening of the dorsal arch, or the other causes that modify the results, but do not alter the principle demonstrated in the above figure.

We shall find this principle run through the whole of the Mammalia.

33. *Examples in the Ass, the Sheep, the Pig, and the Dog, Plate XXVIII. fig. XI.*.*

In the Ass†, whose costal cartilages are unyielding and firmly united to the rib, the six superior ribs, which gradually lengthen, hinge from the upper curve of the dorsal arch; when they are raised, they all approach nearer to each other, the lowest of them, from its increased length, being more raised anteriorly than the rest. The seventh

* Drawings are deposited in the Archives of the Royal Society, showing the position of the ribs and muscles, when the lungs are flaccid (expiration), and when they are distended (inspiration), in the Ass (fig. X. *a. b.*), the Pig (fig. VII. *a. b.*), the Sheep (fig. VIII. *a. b.*), the Dog (fig. XI. *c. d. e. f.*). These figures will be referred to in foot-notes.

† Fig. X. *a. b.* Archives of the Royal Society.

and eighth ribs are linked anteriorly to a common cartilage; their vertebral articulations occupy the hollow of the arch; when they are raised they retain their original distance. The six ribs below these have floating cartilages, hinge with the lower curve forward of the vertebræ, either immediately below or a little in front of each other, and they, when raised, become further apart.

In the Pig* and the Sheep†, whose short and firm costal cartilages articulate by joints both with the sternum and the ribs, the superior six (in the Sheep seven) ribs gradually lengthen; they hinge on the superior curve of the dorsal arch, and when raised they come nearer to each other; the two next ribs have united cartilages, and are neutral; while the lower ribs during inspiration become more remote.

In the Dog‡, whose costal cartilages are long and flexible, permitting free thoracic play, during inspiration the superior six ribs approach each other; the next two are neutral, and the remainder are more distant.

Man too partakes in this arrangement. Plate VII. figs. XIII. *a. b.*, XIV. *a. b.*, XV. *a. b.*

34. *Three sets of ribs. The superior, or thoracic; the inferior, or diaphragmatic; and the intermediate.*

The longest ribs which hinge on the hollow of the dorsal arch, and which neither approach to, nor recede from, each other during inspiration, form as it were a neutral ground between the superior ribs that approach to, and the inferior that recede from each other. The superior ribs, with their costal cartilages, form a complete circuit with the vertebræ and sternum to enclose the lungs and heart; it is their motion, increasing the area within them, that constitutes true thoracic inspiration; these form the thoracic set of ribs. The inferior ribs, each tipped with a floating cartilage, flank the abdomen on each side, have between them an open space in front, and give origin to the diaphragm; these form the diaphragmatic set of ribs. Their action is in aid of diaphragmatic respiration, their office being to enlarge the area of the chest simultaneously with the descent of the diaphragm, without which descent they would act, not on the lungs, which unless drawn down by the diaphragm are above them, but on the abdominal viscera, the more important of which it is their duty to protect. The intermediate set of ribs share duties with each of these sets, forming with the superior set thoracic, with the inferior, diaphragmatic ribs.

35. *The proportion of the thoracic to the diaphragmatic ribs depends on the proportion of the upper lobes of the lungs to the lower.*

The relative proportion that the sterno-vertebral ribs, or those of thoracic respiration, bear to those of diaphragmatic respiration, depends on the size and form of the upper lobes of the lungs, compared with the lower.

In the Ass, the upper lobes are small and narrow, the lower are large and full at their posterior part. The lungs are short in front at the sternum, long and broad

* Figs. VII. *a. b.* Archives of the Royal Society. † Fig. VIII. *a. b.* *ibid.* ‡ Fig. XI. *a. b. c. d.* *ibid.*

behind and below. The superior (or anterior) part of the chest is narrow, the diaphragm is very oblique, the diaphragmatic ribs are numerous, and their expanding movements great.

In the Dog, the body of the lungs and the upper lobes are large ; they are nearly as long in front as behind. The base of the lung is horizontally concave ; the diaphragm is drawn down almost as far in front as it is behind ; the thoracic ribs are numerous, and have great play, at once deepening and widening the chest to a great extent. The diaphragmatic ribs are few in number.

§§ 36-54. ANIMALS THAT HAVE UNYIELDING COSTAL CARTILAGES—THE PIG, THE CALF (Plate XXVII. fig. IX.), THE SHEEP AND THE ASS.

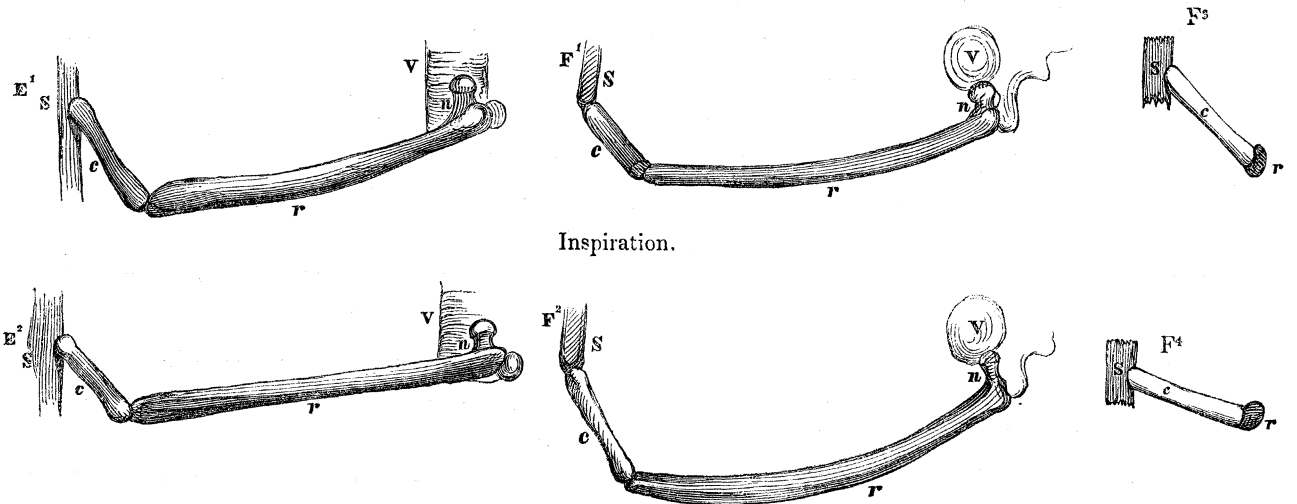
§§ 36-43. COSTAL MECHANISM.

§§ 36-41. *Thoracic set of ribs.*

36. In the Pig* the straight costal cartilages articulate by moveable joints with the sternum and the sternal ribs. The seventh and eighth costal cartilages are linked together. During inspiration the six superior ribs are raised and drawn nearer to each other ; the articulation with the cartilage is drawn slightly forward, and that with the vertebra backwards ; the sternum is pushed forwards by the cartilages riding on the ribs. The superior curve of the dorsal arch is increased, the attachment of each of the ribs being further back in relation to that above in inspiration than in expiration. The extent to which the sternum and vertebræ are pushed further apart is inconsiderable ; this is due to the great lateral expansion.

37. *The elevation of the ribs increases the depth and width of the chest. Diagrams E^{1,2}, F^{1,2-3,4}.*

The diagrams E¹ and E² are side views, F¹ and F² views looking as it were down
Diagrams.
Expiration.



E¹ E² side views.

F¹ F² views looking down into the chest ; a transverse section.

F³ F⁴ front views.

* Fig. VII. a. b. Archives of the Royal Society.

into the chest, and F^3 and F^4 are front views of the rib of a Pig. E^2 shows the forward and backward thrust on inspiration, or increased distance between the sternum S and vertebræ V , and $F^{2,4}$, show the lateral thrust. The sternum S and vertebræ V not admitting of further separation, the raised costal cartilage acts like a crank on the end of the rib jointed to it, and pushes it outwards. The area of the chest between the opposite ribs is thus increased, and the elevation of the rib and cartilage is extended in two directions, one direction (E^2) to increase the depth, the other (F^2) the width of the chest.

38. In the Pig, as we have seen, the elevation of the rib and cartilage is distributed in two directions, one direction forwards and backwards, the other outwards. The outward, or lateral thrust, is by far the greatest. There is in the Calf considerable forward movement of the sternum in addition to the lateral expansion. The lower costal cartilages are longer than the upper, consequently the lower part of the sternum is thrust further forward than the upper, exactly as it is in birds, and for the same reason (§ 22).

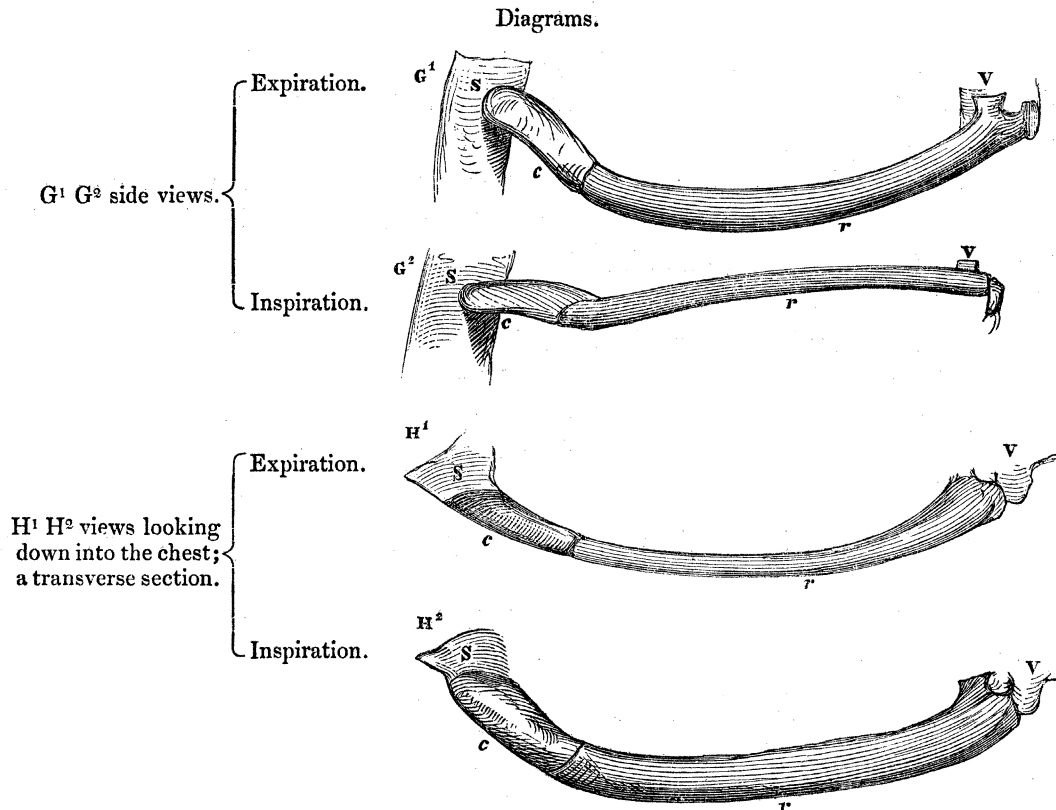
In the Sheep, when the lungs are distended, the vertebræ are, I believe, pushed slightly backwards, but nearly the whole of the force is expended in the lateral thrust; the chest, though but slightly deepened, is much widened.

39. *Inspiratory changes in the position of the curves and surfaces of the ribs.*

The space between the ribs is further increased by the change in profile of the curves of the ribs. In expiration the upper edge (diagram E^1) and the inner surface of the rib (diagram F^1) are each slightly curved. In inspiration (diagram E^1), when the rib is raised, the curve of the inner surface is very greatly increased at the expense of that of the upper edge, the curve of which entirely disappears, giving place to a straight line; the form of the rib remains the same, but its profile and the direction of its surfaces are changed.

40. *Lateral expansion of the chest from the varying profile of the curves of the ribs in the Ass.*

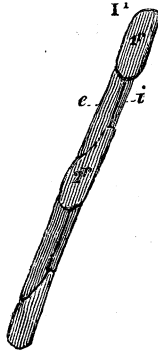
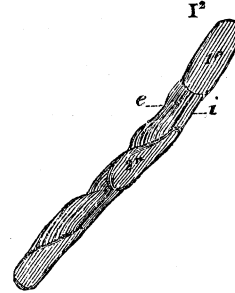
In the Ass, the unyielding cartilage is firmly fixed to the rib so as to form one piece with it. The whole of the lateral thrust is due to the different direction of the costal curves. Nearly the whole of the respiratory movements go to increase the width of the chest. The sternal end of each cartilage is a little raised, and the vertebral end of the rib is slightly depressed; the sternum moves forwards and upwards with the cartilages; the spinal column backwards and downwards with the ribs; the increase in depth is very slight.



Diagrams G¹ and G² represent side views, and H¹ and H² views as if looking downwards into the chest, of the rib of an Ass, as in expiration G¹, H¹, and inspiration G², H². The downward curve of the upper edge in expiration, G¹, becomes in G², inspiration, a slightly upward curve; G¹ presents a flat surface, G² a thin edge. In H¹, expiration, there is a slight curve on the inner surface; in H², inspiration, the curve is deepened; and the flat surface of the rib is presented instead of the edge, as in H¹. In fact that curve that looked upward in expiration G¹ looks inward in inspiration H², and the lateral surface in G¹, expiration, becomes in H², inspiration, the superior surface.

41. *On inspiration. The oblique internal surface of the superior ribs is more nearly horizontal. Diagram I¹ I².*

In the Pig, the Sheep, the Calf, and the Ass, the direction of the inner surface of the ribs is beautifully adapted to the lungs. The lungs gradually narrow from their body upwards to the summit; the interior of the chest forms as it were a dome at its upper part, to contain the upper lobes; the inner surface of the rib, which on expiration is nearly vertical, becomes on inspiration much more oblique. The dome of the chest is thus increased.

Diagram I¹. Expiration.Diagram I². Inspiration.

Section of the three superior ribs and their intercostal muscles (from the Ass).

I¹. Expiration. I². Inspiration.

1 r. First rib. 2 r. Second rib.

e. External intercostal. i. Internal intercostal.

42. *Diaphragmatic set of ribs.*

The posterior angles of the free or diaphragmatic set of ribs, whose cartilages are floating, are drawn considerably backwards. They thus increase the area between the opposite ribs in the manner demonstrated in the Snake (diagrams B 1.2. § 9). The space in front between the cartilages of the two sides is widened. The upper edge of each of these ribs, except the two or three lowest, glides backwards in relation to the lower edge of the rib above (§ 6. 7). The gliding motion that would result from the elevation of the two or three lower ribs (diagram A 1.2) is, I believe, quite neutralized by the greater degree to which the rib immediately above each of them is drawn backwards. Corresponding with the gliding movement of rib on rib, each cartilage glides downwards and backwards on that above it; each cartilage forms also a less acute angle with the rib.

43. *Intermediate set of ribs.*

The intermediate or neutral set of ribs (two in the Sheep and Pig, three in the Ass), whose cartilages united to each other articulate with the lower end of the sternum, neither approach to nor recede from each other during inspiration. The elevation of the superior rib acts to raise the rest. The bodies of the ribs move outwards, their posterior portion backwards, their cartilages slightly forwards, and the angle between the cartilages of the two sides below the sternum is enlarged. These intermediate ribs partake of the motions both of the ribs of thoracic respiration superior to them, and of the diaphragmatic ribs inferior to them. The distance between the lowest of the intermediate set of ribs and the highest of the diaphragmatic set is greatly increased on inspiration.

In the Ass, the lowest costal cartilages articulating with the sternum are so firm, that they form, with the set of three intermediate ribs, one unyielding piece.

§§ 44-54. MUSCLES ACTING ON THE RIBS.

44. The actions of the costal muscles are entirely subservient to the motions of the ribs. We cannot comprehend the actions of the muscles unless we rightly understand the movements of the ribs.

45. *In Birds and in Snakes all the external intercostals are inspiratory, and all the internal intercostals are expiratory.*

In birds, still more so in the Snake, the ribs are similar throughout and they all go through analogous motions. The snake has no sternum and sternal ribs; the bird has no set of diaphragmatic ribs with floating cartilages; all its lower vertebral ribs articulate with sternal ribs. All the external intercostals are inspiratory, all the internal expiratory (§§ 6-8).

46. *In Mammalia the superior intercostals have the opposite action to the inferior, because the superior and inferior ribs have opposite motions.*

When I exposed the muscles of the living and breathing Ass, I was surprised to find that while the superior external intercostal muscles were invariably inspiratory, the inferior were as invariably expiratory, and that while the posterior fibres of the same muscle were inspiratory, the anterior were expiratory. These were the facts; I could not gainsay them. It was only after much inquiry that they became intelligible, not until I had comprehended the varying movements of the ribs at different parts; then everything, step by step, became lucid.

The sole duty of the muscles is to move the ribs. It is not because two muscles, between two distinct pairs of ribs, have the same direction of fibres and the same name, that they perform the same functions; it is because the two sets of ribs go through the same motions simultaneously. If one set of ribs, the superior, approach each other, while the other, the inferior, go further apart, on each inspiration, ought we not, *à priori*, to infer that the two sets of muscles passing between the two sets of ribs will have different functions? that if the muscle between two superior ribs that approach each other be inspiratory, that between two inferior ribs that recede from one another will be expiratory? In truth we ought to infer this, for the fact is so. In fact it is not the system of muscles, but the system of ribs that we must regard.

47. *Scalenus.*

In the Pig, the Sheep and the Calf, in addition to the scalenus of the first rib, there is another scalenus that acts on a few of the superior ribs to raise them on their outer surface. The Ass possesses no scalenus save that of the first rib. This scalenus scarcely raises the first rib at either end, but it raises the rib at the centre, and converts the upward into an inward curve.

48. *Intercostal muscles of the thoracic set of ribs.*

By comparing the views of the Sheep, Pig, and Ass* in expiration with those of the same animals in inspiration (the lungs distended), we shall comprehend at a glance what muscles are shortened on inspiration, what on expiration; where the muscles are shortest in *a*, they are expiratory; where they are shortest in *b*, they are inspiratory.

During inspiration in the Sheep†, the first six external intercostals are shortened throughout. The superior ribs approach each other more than the inferior, the anterior third of each rib moves forward, the posterior two-thirds are drawn backwards, and the gliding motion of rib on rib is greater behind than before; hence the superior muscles shorten more than the inferior, the posterior fibres more than the anterior. The seventh intercostal space widens posteriorly; its muscle is shortened behind but lengthened in front, especially where it is inserted into the cartilage, which it bends on the rib in expiration.

During inspiration in the Ass‡, the six superior external intercostal muscles shorten, all save the anterior portion of the sixth, and the portions of the fourth and fifth inserted into the fifth and sixth costal cartilages. A great portion of the action of the external intercostals is spent in making the oblique inner surface of the rib more horizontal. The fibres draw upwards the outer part of the rib, while the inner part is stationary, as diagram I². § 41 represents, and as is well seen in the third rib of the Ass. The gliding motion of the anterior portion of the ribs of the Ass is slightly reversed owing to each rib and cartilage forming one piece. The anterior half of the five superior conjoined ribs and cartilages moves forwards; the posterior half of those ribs backwards; the whole of the sixth, and to a greater extent, the inferior ribs, move backwards, though less in front than behind. The sixth, seventh, eighth and ninth cartilages either move forward or are stationary.

The whole of that portion of the internal intercostal between the cartilages shortens on inspiration, that part of the muscle having the same action on the cartilages that the external intercostal has on the ribs, raising and approximating them, and making them glide on each other. The fourth, fifth and sixth muscles between the ribs are throughout expiratory. During inspiration, the first, second and third ribs come so much nearer to each other in front that the tendency of the fibres to make the lower rib glide backwards is counterbalanced: about four-fifths of the first, one-third of the second, and a small portion of the third internal intercostal muscles between the ribs in their anterior portions are inspiratory; here the outer and inner layers of intercostals act at the same time by a mutual diagonal pull.

49. *Intercostal muscles of the diaphragmatic and neutral sets of ribs.*

The anterior fibres of the external intercostal muscles between the diaphragmatic set of ribs are lengthened, and the posterior fibres are shortened, during inspiration; the ribs move further apart, and are all drawn backwards through their whole extent,

* Fig. VIII. *a.b*, VII. *a.b*, X. *a.b*. Archives of the Royal Society. † Fig. VIII. *a.b*. *ibid*. ‡ Fig. X. *a.b*. *ibid*.

though more posteriorly than anteriorly; the two or three lowest ribs do not glide on each other. The lower external intercostals are almost entirely expiratory, as in them the gliding action and the separation of the ribs in some measure counterbalance each other, the fibres of the muscle being either expiratory or inspiratory, as the one action or the other overbalances. In the Sheep*, the three lowest muscles are divided into two portions, the anterior being expiratory, the posterior inspiratory.

The fibres of the external intercostals between the floating cartilages contract during inspiration, causing the upper edge of one cartilage to glide backwards on the lower edge of that above; we have thus a curious distribution of opposite functions in the same muscle, the anterior fibres, those between the cartilages, being inspiratory, the middle, between the fore-part of the ribs, expiratory, and the posterior, inspiratory. The whole of the internal intercostal muscles are expiratory, both those fibres inserted into the cartilages and those into the ribs. We have then a complete transposition of functions in many parts of these muscles; the external intercostals between the ribs being inspiratory above, expiratory below, those parts between the cartilages being expiratory above and inspiratory below.

The muscles between the neutral or intermediate set of ribs are almost neutral in action.

50. *Levatores costarum.*

The whole of the levatores costarum are inspiratory; they draw upwards and thrust outwards the angle of the rib, elevate the ribs behind and pull backwards the posterior part of the diaphragmatic (diagram B. § 9), the intermediate, and a portion of the thoracic sets of ribs. They assist the external intercostal in making the upper edge of one rib glide backwards on the rib above (§ 6. 7), and in so thrusting backwards the vertebræ with which the rib articulates.

§§ 51-54. CERTAIN MUSCULAR ACTIONS OF THE ASS OBSERVED ON VIVISECTION.

51. *In the Ass the fibres of the serratus magnus are expiratory above, inspiratory below, neutral in the centre.*

In the Ass, I observed, on vivisection, that during inspiration the two lower fibres of the serratus magnus were shortened, acting on the ribs of the intermediate set, which were drawn backwards in their whole extent; the origins at the scapula of the two lowest fasciculi of the serratus magnus are above the articulation with the vertebræ of the two ribs on which they act. The sixth fasciculus of the serratus to the sixth rib was neutral, neither expiratory nor inspiratory. That to the fifth shortened very slightly on expiration; all the superior fibres acting on the first, second, third and fourth ribs acted very decidedly to draw down those ribs on expiration. The articulations of these ribs with the vertebræ are considerably above the attachment of the serratus to the scapula; the centre of action of the serratus being considerably

* Fig. VIII. Archives of the Royal Society.

below the centre of motion of the ribs ; the fibres fixed into those ribs act in relation to the ribs from below upwards and forwards to draw them downwards, and slightly backwards. We have here this curious fact, that the superior fibres of the same muscle, the serratus magnus, are expiratory, while the inferior fibres are inspiratory. The action of this muscle can only be demonstrated on the living body, but we might have inferred, *à priori*, on knowing the relative direction of the various fasciculi of the serratus and of the ribs into which they are respectively inserted, which fibres are expiratory and which inspiratory.

The serratus is in full stretch when the animal stands, and then it acts from the ribs on the base of the scapula : if all its fibres were expiratory, it is clear that when the scapular action is called into play, as the expiratory action would be constant, inspiration would be interfered with. If all were inspiratory, the expiratory action would be clogged. As it is, the central fibres which support the scapula are neutral, the superior expiratory, the inferior inspiratory, and by this beautiful adjustment every action of the muscle is unembarrassed.

52. *Serratus posticus superior.*

The whole of the eight fibres of the superior serratus posticus I found to act during inspiration.

53. *Serratus posticus inferior, superior fibres expiratory, inferior inspiratory.*

The four lower fibres of the serratus posticus inferior acted during inspiration to draw backwards the four inferior ribs, the two superior fibres of the same muscle acted, during expiration, on the eleventh and twelfth ribs to draw them downwards, while the fibres acting on the thirteenth and fourteenth ribs appeared to be neutral. The tendency of all the fasciculi of the inferior serratus would be from their direction to draw the ribs both downwards as in expiration, and backwards as in inspiration ; the proportion in which the four lower ribs are drawn backwards overbalances that in which they are drawn downwards, and their fibres are inspiratory ; but the proportion in which the eleventh and twelfth ribs are drawn downwards overbalances that in which they are drawn backwards, and their fibres are expiratory ; as the downward and backward motions of the thirteenth and fourteenth ribs balance each other, the fibres acting on those ribs are neutral.

54. *Expiratory muscles.*

I observed the following muscles to act during expiration : the rectus abdominis, which draws down the sternum slightly, and the fibres inserted into the first rib arising from the tendon of the rectus ; the external oblique, which pulls downwards and forwards the diaphragmatic ribs and a portion of the superior ribs ; the inferior oblique, which draws down the lower ribs and their costal cartilages ; the transversales, which draw nearer to each other the diaphragmatic ribs of the opposite sides, contracting the abdomen ; and the sacro-lumbalis.

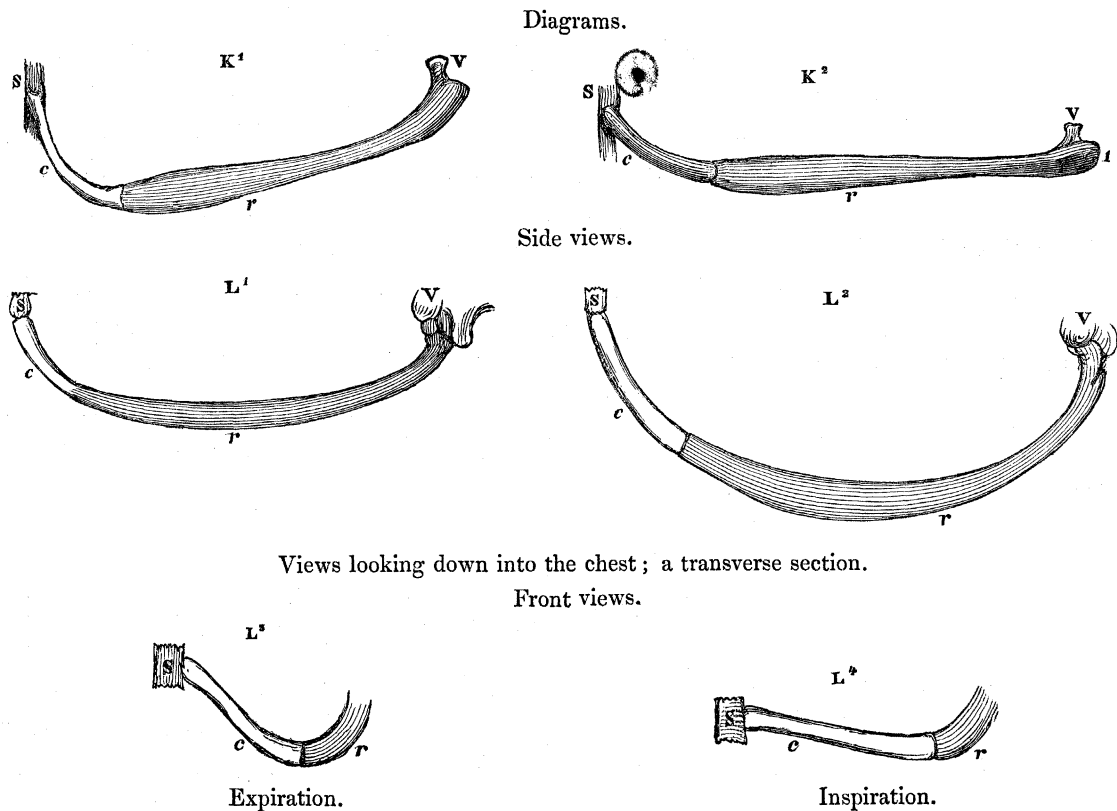
§§ 55-57. ANIMALS WITH FLEXIBLE CARTILAGES—THE DOG (Plate XXVII. fig. X.), THE SEAL (Plate XXVI. fig. VIII.), THE RABBIT (Plate XXVIII. fig. XI.), THE OTTER (Plate XXVIII. fig. XII.) and THE MONKEY.

§§ 55-57. COSTAL MECHANISM.

55. *The Dog, Seal, Rabbit and Monkey.*—In the Dog and its allied species, the Seal and the Otter, and in the Rabbit and the Monkey, the costal cartilages are long, slender and flexibly elastic; they are firmly fixed to the ribs, and they articulate with the sternum. In the Dog and the Rabbit the articulation with the sternum is by a horizontal chisel-end that is united to it by a ligament, and moves freely upwards and downwards. In the Seal and the Monkey the articulation is between a ball-and-socket and a hinge-joint. The flexibility and elasticity of the cartilages permit them to bend and spring on themselves through their whole length. They have, in relation to the ribs and the sternum, exactly the same function and the same principles of action as the sternal ribs of birds, and the straight double-hinging costal cartilages of the Sheep, the Calf, and the Pig.

56. *The inspiratory elevation of the ribs increases the depth and width of the chest.*

Diagrams K^{1,2}, L^{1,2,3,4} represent a rib in expiration ^{1,3} and inspiration ^{2,4}. KK are side views; L¹ L² views looking down as it were into the chest, and L^{3,4} front views.



In inspiration, diagram K², the rib and the costal cartilage are each raised, the eleva-

tion is, as in the Pig (diagrams EF, § 37), distributed in two directions. In one direction (K^2), the vertebræ are thrust backwards by the rib, and the sternum forwards by the cartilage, the chest being deepened; in the other direction ($L^2 L^4$), the outer portion of the rib and cartilage is thrust outward, the posterior portion of the rib is drawn backwards, and the anterior portion of the cartilage thrust forward. The greater and more extensive the play of breathing the longer are the costal cartilages, as we see in the Seal (fig. VIII.), and to a less degree in the Otter (fig. XII.). Both of these animals require very great play of respiration and unusual power to expel and renew the air at each respiration, owing to their diving habits. In the Dog, the Otter, the Rabbit and the Monkey, the first costal cartilage is stiff, and is firmly impacted in the sternum; in the Seal, the first rib is long and flexible, and hinges moveably on the sternum. During inspiration in the Dog* all the ribs are drawn backwards, the superior ribs to a less extent than the inferior: the first, second and third ribs are stationary at the anterior extremity, but all the rest move backwards through their whole extent, though more posteriorly than anteriorly.

57. *The thoracic and diaphragmatic sets of ribs*.*

The upper edge of each rib glides backwards in relation to the lower edge of that above, and at the same time the upper edges of those costal cartilages that hinge on the sternum have a reverse direction, and glide forwards and inwards in relation to the lower edges of the respective cartilages above. The superior ten cartilages articulate moveably with the sternum, the tenth imperfectly. The ten superior ribs act as ribs of thoracic expansion; as the diaphragm ascends behind the sternum some distance into the chest the three lowest of them act with the eleventh, twelfth and thirteenth, or diaphragmatic set of ribs, to expand the chest when the diaphragm descends (see §§ 34. 35).

The floating cartilages of the three lowest ribs glide in the same direction as the ribs on which they ride; the upper edge of each cartilage sliding backwards in relation to the lower edge of the cartilage above. The six superior ribs approach each other, especially anteriorly; the seventh, eighth and ninth, are about neutral; all the lower ribs recede from each other.

58–69. MUSCLES ACTING ON THE RIBS.

58. *The scaleni of the superior five or six ribs are much developed.*

The scaleni are very greatly developed in all those animals with flexible cartilages. The scaleni of the first rib are very insignificant in the Seal and Otter, whose cervical vertebræ are very moveable; while they are well-developed in the Rabbit and the Monkey, whose necks are less moveable.

These animals all have long and powerful scaleni that pass over the first two ribs and are inserted into the ribs below them near their costal cartilages; in the Dog

* Fig. XI. *c.d.e.f.* Archives of the Royal Society.

their insertion extends to the eighth; in the Otter and Monkey to the sixth; and in the Seal and Rabbit to the fifth ribs. The scaleni act during the whole time of inspiration to pull upwards the ribs into which they are inserted.

59. *Sterno-mastoid, &c.*

The sterno-mastoid, sterno-hyoid and thyroid muscles, when they act from above, raise the sternum; when the sterno-hyoid and thyroid so act, their origins are fixed by the genio-, and stylo-hyoid and the hyo-thyroid.

60. *External intercostal muscles.*

The actions of the external and internal intercostals are in principle the same as those of the Ass and Sheep, varying as the ribs' movements vary (see §§ 46. 48. 49).

The first seven external intercostal muscles, where they pass from rib to rib, are inspiratory; the eighth (perhaps the ninth) are neutral anteriorly, and are inspiratory posteriorly.

The fibres from the third, fourth and fifth ribs inserted into the costal cartilages are neutral, but those inserted into the seventh, eighth, ninth and tenth cartilages, which in the latter pass from cartilage to cartilage, are all strongly expiratory; they bend the cartilage on the rib, and cause the upper edge of the lower cartilage to glide forwards in relation to the lower edge of the upper; movements the reverse of inspiratory. The three lowest external intercostals are inspiratory posteriorly, expiratory in the middle, where they act on the anterior portion of the ribs, and inspiratory anteriorly, where they pass from cartilage to cartilage; the anterior fibres cause the cartilage they are inserted into to slide downwards, outwards and backwards in relation to the cartilage from which they rise.

61. *Internal intercostal muscles.*

The first internal intercostal between the rib is inspiratory on its anterior four-fifths, the second and third in their anterior half and third; posteriorly they are expiratory; all the lower muscles between the ribs are expiratory; the expiratory action being less extensive in the superior than the inferior ribs, and in their anterior than their posterior portion. The fibres inserted into the ten superior cartilages are inspiratory, having the same relation to these cartilages that the external intercostals have to the ribs they are fixed to.

The internal intercostals between the three? lowest cartilages are expiratory.

62. *Elevator of the first costal cartilage in the Seal, Plate XXVI. fig. VIII. 10 a.*

In the Seal, whose flexible first costal cartilage hinges on the sternum, a muscle arises from the sternum and is inserted into the first cartilage that is analogous with the internal intercostal fibres between the cartilages, and which, like them, is inspiratory.

63. *Serratus magnus, expiratory above, inspiratory below.*

I observed in the Dog, as in the Ass, the superior fibres of the serratus magnus to be expiratory, the inferior inspiratory, and those fibres in the centre neutral, § 51.

64. *In the Dog : serrati postici, superior fibres inspiratory, inferior expiratory.*

The serratus posticus superior (fig. X. 10) was throughout inspiratory. The serratus posticus inferior (fig. X. 11) was expiratory, its depressing action on the ribs overbalancing any action it might have to draw them backwards. The Seal (fig. VIII.) has a middle serratus posticus. See § 53.

65. *In the Rabbit, both serrati postici are inspiratory.*

In the Rabbit (fig. XI.) I observed that both serrati postici were throughout inspiratory; indeed their fibres are so amalgamated that they form one muscle. The diaphragmatic ribs of the Rabbit, which are far apart, are drawn far backwards on inspiration by the combined influence of the serratus posticus and the levatores costarum.

66. *Expiratory muscles.*

I observed that the rectus abdominis, the external oblique, the transversalis, and the sacro-lumbalis, all acted on expiration.

67. *Varieties in the rectus, external oblique, and depressor of first rib.*

The rectus (16) is inserted in the Otter (fig. XII.), fleshy into the first rib; in the Dog (fig. X.) and Monkey it is inserted into the sternum, its whole length, by a tendinous aponeurosis, from which arises a fleshy depressor of the first rib (16 a.). In the Rabbit (fig. XI. 16 a.) this depressor arises from the sternum and passes in front of the rectus; it does the same in the Seal (fig. VIII. 15), but in this animal it forms the first fibre of the external oblique (17), which combines with fibres to the first (15), second (15 a.) and third (15 b.) costal cartilages, to form one vast external oblique inserted into all the ribs.

68. *The triangulares sterni and the transversales combine to form one large muscle.*

The triangulares sterni (19) form in the Dog*, the Seal † and the Otter ‡ one continuous web with the transversales (20); in fact the triangulares sterni combine with the transversales to form one extensive muscular web, the vast constrictor of the chest and abdomen that arises from the posterior surface of the sternum, from the xyphoid cartilage and from the linea alba, and is inserted successively into the anterior extremities of all the ribs from the second to the lowest, which ribs it draws downwards and inwards during expiration to constrict the chest and abdomen.

* Fig. XI. b. Archives of the Royal Society.

† Fig. VIII. b. *ibid.*‡ Fig. XIII. b. *ibid.*

69. *The Seal; great respiratory apparatus.*

The Seal (fig. VIII.), of all the animals we have yet considered, has by far the most capacious chest; compare its large breathing apparatus and small abdomen with the small chest and enormous paunch of the Rabbit (fig. XI.). The chest of the Seal admits of very great expansion and contraction. Its slender ribs and very long flexible costal cartilages, its peculiarly deep dorsal arch, the great size of its levatores costarum, and the development of its intercostals, its external oblique, transversales and sterno-costals, all combine to give it very great power both of expiration and inspiration. The respiratory development is entirely thoracic, the scaleni having less action from the neck in this than in any animal we have yet examined.

PORPOISE, Plate XXVI. fig. VII. §§ 70-77.

70. *The Porpoise has a large portion of lung in the neck.*

The Porpoise, to which we now turn, has a development of respiratory power far greater even than the Seal. In addition to the usual thoracic and diaphragmatic space for breathing, this animal has a large portion of lung occupying the neck; in this it contrasts remarkably with the Seal.

The whole build of the Porpoise corresponds with this great cervical respiration. Its cervical vertebræ are all amalgamated to form one bone, on which the head has but little motion. The first and the succeeding five ribs articulate with long, slender, almost bony costal cartilages or sternal ribs, having moveable joints at each extremity. The sternum is broad and hollow within. The diaphragmatic ribs are six in number; of these the superior only has a costal cartilage.

The first rib has, owing to its long double-jointed costal cartilage, very great play in respiration.

71. *A peculiar scalenus (1 a.); the sterno-hyoid and sterno-thyroid, while they act on the first rib and sternum, also expand the lung in the neck.*

The lungs rise up into the neck almost as high as the base of the skull; they are almost surrounded by muscles, having in front very powerful sterno-hyoid (13) and sterno-thyroid (14) muscles, and to the side, and behind, a large and very peculiar scalenus (1 a.). This scalenus is like the half of a funnel or hollow cone; it arises tendinous from the base of the skull, descends, and soon forms a hollow fleshy web that increases as it descends, half embraces the large portion of lung in the neck, and is inserted into the whole circuit of the first rib, and the costal half of the first costal cartilage. There is yet another scalenus to the outside of this, which is much shorter and smaller, arises from the vertebral transverse process, and descends obliquely forwards to the first rib.

The sterno-hyoid, sterno-thyroid, and large scaleni, all join to complete a circuit embracing the lungs behind, in front, and on each side, the vertebræ being, of course, behind, the larynx and pharynx between the lungs. When these muscles all act toge-

ther in inspiration, they raise the sternum, the first ribs, and their costal cartilages. The sternum moves forward, the first ribs and cartilages move sideways, and the whole circuit is increased, the brim of the chest being at once widened and deepened. As the sternum and costal cartilages move forwards and outwards, they carry forward with them the sterno-hyoid and thyroid muscles; and as the first ribs move outwards and backwards they carry the scaleni outwards and backwards, so that the same muscles that raise the sternum, first costal cartilages and first ribs, and increase the circuit they embrace, are in turn pushed forwards, outwards and backwards by the parts they raise, and the space for the lungs in the neck that they encircle is everywhere increased.

72. *The scaleni do not move the vertebræ laterally, though they draw them forwards and downwards in inspiration.*

In the Porpoise we have found that the scalenus is enormously developed although the cervical vertebræ are quite destitute of motion; in the Seal, whose neck is remarkably flexible, the scaleni are quite insignificant (§ 58). It is very evident that the scaleni do not act to draw the vertebræ to either side; how can they in the Porpoise? and in the Seal, whose neck is so bending, why are they not unusually developed? it is because they do not act on the vertebræ laterally, and because the mobility of the vertebræ would interfere with their action on the ribs.

We find all through that the scaleni are small in those animals whose necks are mobile, and large in those that have inflexible necks. Though the scaleni do not move the vertebræ sideways, they do draw them downwards and forwards, at the same time that they raise the first ribs. The two fixed points in fact approach each other.

73. *The combined triangulares sterni and transversales form one vast constrictor of neck, chest and abdomen, which rises into the neck.*

The development of the scalenus, sterno-hyoid and thyroid, to cause the expansion of the lungs in the neck, is counterbalanced during expiration by the development in a remarkable manner of the sterno-costal, or triangulares sterni muscles (see § 68)*. In the Porpoise, the upper portion of these muscles, that in all other animals rises only to the second rib, ascends quite into the neck, embraces the lower half of the cervical portion of lung, and is inserted into the whole circuit of the first rib. In the Porpoise, as in the animals we formerly examined (§ 68), the sterno-costal muscles unite with the transversales; and they unite to form an enormous muscle, one vast constrictor of the neck, chest, and abdomen. This combined muscle arises from the sternum and linea alba, and is inserted into all the ribs. With the aid of the other expiratory muscles, it constricts the neck, chest, and abdomen, and thrusts, through the intermedium of the abdominal viscera, the large and bulging diaphragm almost quite up into the neck.

* Fig. XVI. c. Archives of the Royal Society.

74. *Special inspiratory muscles in the Porpoise, Plate XXVI. fig. VII. 27.8.8.*

There is no scalenus to any rib save the first; a muscle (27) passes from the cervical transverse process to three or four of the superior ribs that must act to raise them; and muscular fibres (8.8) pass from the first rib just below the insertion of the scalenus, and from the second rib to be inserted into the third, fourth and fifth ribs; these muscles are probably also inspiratory.

75. *The serrati postici are amalgamated, fig. VII. 10.11.*

The serrati postici are, in the Porpoise, amalgamated to form one muscle, or at least one tendinous web; the fibres to the lower edge of the sixth rib mingle with those to the upper edge of the seventh; the two fasciculi above are inserted into the upper edges of the ribs; those below into the lower edges.

76. *Internal oblique.*

The internal oblique passes from rib edge to rib edge to be inserted into the anterior ends of the seven lower ribs.

The great caudal muscle is attached to the five lowest ribs.

77. *Power of the Porpoise to remain long under water accounted for.*

The true source of the power enjoyed by the Porpoise to remain so long under water is, I conceive, its capability of renewing almost the whole volume of air that is contained in the lungs at each inspiration, as the complete preceding expiration leaves scarcely any adulterated air in the lungs.

The animal may descend under water with a far purer and far larger stock of air than land animals can, by any effort, obtain; of course when the animal dives very deep the quantity of air in the chest cannot be great.

MAN, §§ 78–100. Plate XXIX. figs. XIII. *a. b.*, XIV. *a. b.*, XV. *a. b.*

78. All the creatures we have hitherto examined are in some measure illustrative of the mechanism of respiration in Man. In some point or other he partakes in structure with each of them.

His three lowest, the floating ribs, resemble the simple vertebral ribs of the Snake. His sternum and costal cartilages are analogous to the sternum and spinal ribs of birds. In the possession of an intermediate set of three ribs, the sixth, seventh and eighth, whose cartilages are all linked together, and which partake of the functions of the thoracic set of five ribs above, and diaphragmatic set of four ribs below, he resembles the Calf, the Ass, the Sheep and the Pig. He has flexible and elastic costal cartilages fixed to the rib and hinging on the sternum, in common with the Seal, the Dog, and the Rabbit. He has a large portion of lung in the neck, like the Porpoise, subject to cervical respiration, and he possesses a clavicle and flat superior sternal bone, and other points that ally him with the Monkey. Having broken ground by

examining the machinery of breathing in these creatures, we shall find little difficulty in investigating that machinery in Man.

The various drawings (figs. XIII. *a. b.*, XIV. *a. b.*, XV. *a. b.**) are from the human subject. They are in pairs and represent the same subject, and the same view before and after the lungs were distended.

The chest in Man is a cavity of ever-varying capacity, whose walls can be enlarged everywhere simultaneously. The domed roof rises, the floor descends, and the diameter between the walls is increased in every direction.

79. *Dorsal arch; the longest ribs are at the centre of the arch. Thoracic, diaphragmatic and intermediate sets of ribs.* Plate XXIX. fig. XIV. *a. b.*

In Man, as in all other Mammalia (see § 31), the lower part of the sternum is more distant from the spinal column than the upper; a gradual increase in the length of the ribs and the depth of the chest takes place from above downwards. The first rib is the shortest; the ribs progressively lengthen to the sixth; to it the seventh and eighth, which are the longest, are about equal; and the four lowest ribs gradually shorten, the lowest being the shortest.

Man, in common with the other Mammalia, has a dorsal arch (see diagram D 1 and D 2, § 32), the curves of which correspond with the varying lengths of the ribs. The upper curve looks forwards and downwards, and coincides with the gradual lengthening of the five superior ribs which are connected with the sternum by distinct cartilages, and which encompass and expand the upper portion and body of the lungs, and are the ribs of thoracic inspiration (see § 34). The lower curve looks forwards and upwards, and is adapted to the progressive shortening of the four lower ribs which are tipped with floating cartilages, and which enlarge the lower portion of the chest simultaneously with the descent of the diaphragm, and form the diaphragmatic set of ribs (see § 34.35). To the hollow of the arch, at its centre, are fitted the three longest ribs, the intermediate set, or sixth, seventh and eighth, that take part with the five superior ribs in thoracic, and the four inferior in diaphragmatic respiration. The cartilages of these three ribs are linked together, so that when the superior cartilage is raised, the rest necessarily follow.

80. *Changes in the situation of the ribs on inspiration.* Plate XXIX. figs. XIII. *a. b.*, XIV. *a. b.*, XV. *a. b.*

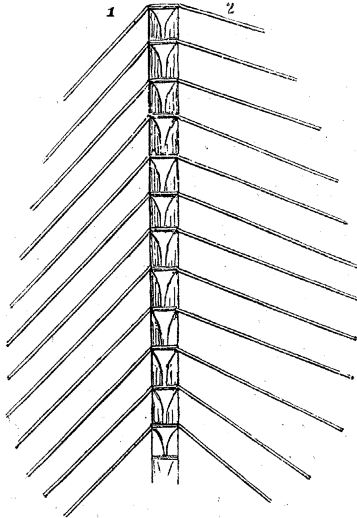
During inspiration the ribs approach to or recede from each other according to the part of the arch with which they articulate; the four superior ribs approach each other anteriorly, and recede from each other posteriorly; the fourth and fifth ribs, and the intermediate set move further apart to a moderate, the diaphragmatic set to a great extent. The upper edge of each of these ribs glides towards the vertebræ in relation to the lower edge of the rib above (§ 6.7), with the exception of the lowest rib, which is stationary.

* Figs. XIX. *a. b.*, XXI. *a. b.*, XXII. *a. b.*, XXIII. *a. b.*, XXIV., XXV. in the Archives of the Royal Society.

The breadth of the chest is considerably greater in proportion to its depth, and the mass of the upper portion of the lungs is greater relatively to the lower portion in Man than in the other Mammalia. The ribs descend first outwards and backwards, then outwards and forwards, and finally forwards and inwards.

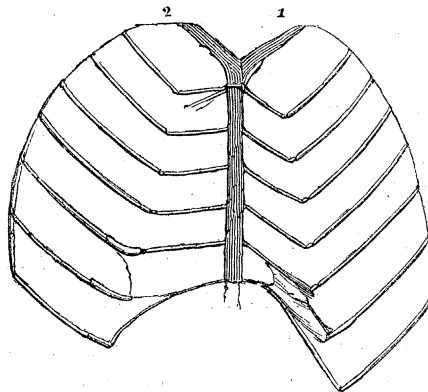
During inspiration all the ribs are raised except the lowest of them; the diaphrag-

Diagram M.
Dorsal view.
1. Expiration. 2. Inspiration.



matic set (see diagram M², fig. XV. *b.*) are not raised so much as the thoracic or the intermediate sets. All the ribs are further apart from each other posteriorly in M 2, fig. XV. *b.* inspiration, than in M 1, fig. XV. *a.* expiration.

Diagram N.
Sternal view.
2. Inspiration. 1. Expiration.



Anteriorly on inspiration (diagram N 2, fig. XIII. *b.*), the costal cartilages, which articulate by moveable joints with the sternum, are raised with the ribs; the upper edge of each cartilage glides towards the sternum in relation to the lower edge of that above it. The second cartilage approaches the first rib, while the other cartilages become more remote from each other, and the angles formed by the ribs with the cartilages become more open. The breadth of the chest is much increased by

the above movements. The cartilages of the intermediate and diaphragmatic sets of ribs of the opposite sides are drawn much further apart, and the distance between them in front is much increased. The angle between the opposite conjoint cartilages of the sixth and seventh ribs below the sternum is enlarged. See diagram N 1.2. and fig. XII. *b*, inspiration, contrasted with fig. XII. *a*, expiration.

On inspiration (see O 2, fig. XIV. *b*.) the anterior extremities of the ribs ascend and move forwards, and carry forwards and upwards the cartilages and the sternum. The posterior angles and extremities of the ribs move backwards and downwards and push backwards, and lower the spinal column. As the *longer intermediate ribs* occupying the hollow of the arch move backwards, from their greater length, more than the other ribs, *their immediate action is to deepen, and consequently shorten the dorsal arch.*

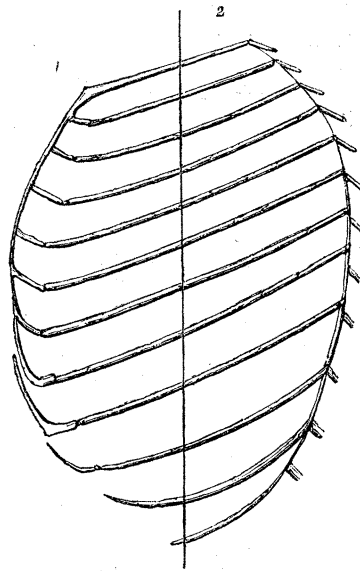
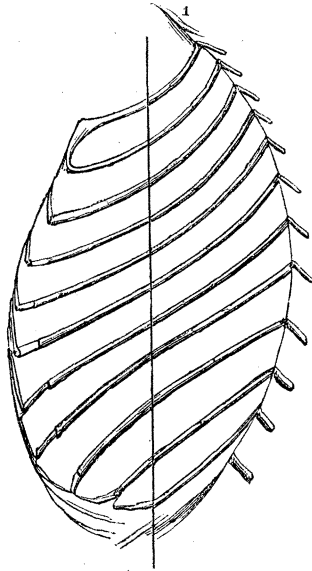
Diagrams.

O.

1. Expiration.

Lateral views.

2. Inspiration.



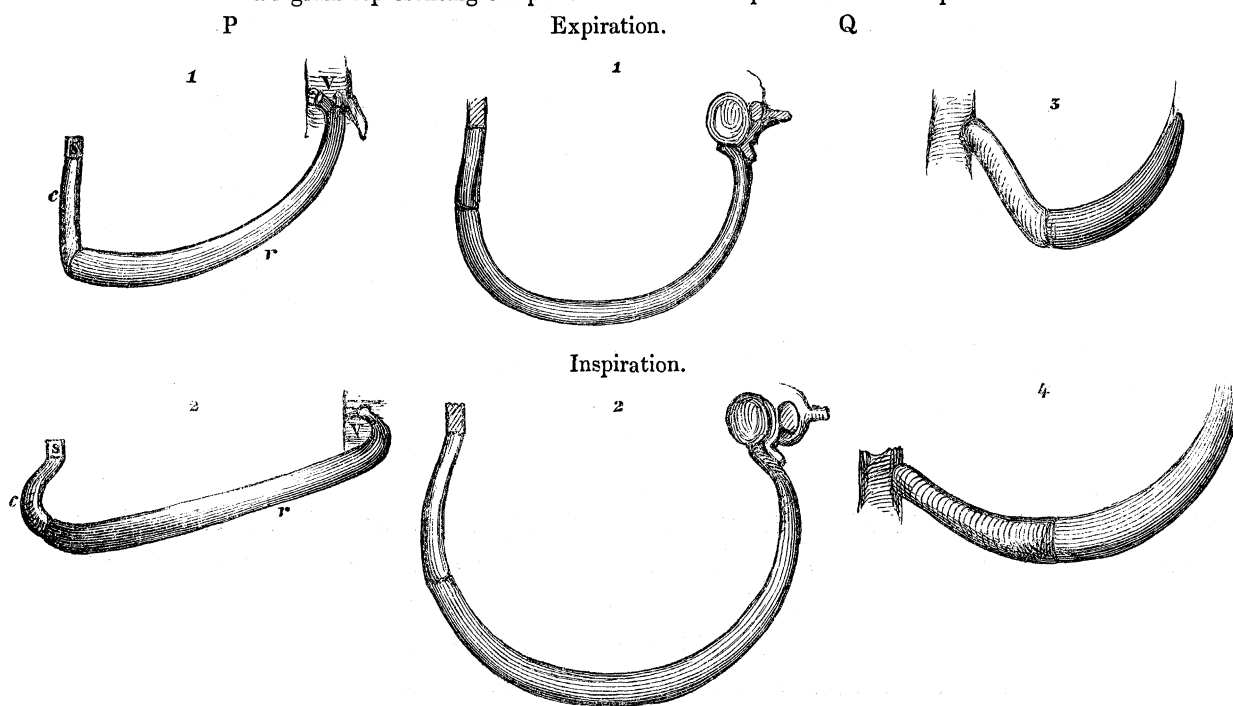
All those portions of the ribs in front of a line O 1.2, drawn from the insertion of the scalenus to the junction of the eleventh rib with its cartilage move forwards and ascend; all behind that line move backwards. This observation can be readily tested; place the thumb firmly on any part of the chest and breathe deeply; if in front of the line indicated, the thumb will be carried forwards; if behind the line, backwards.

On inspiration the costal cartilages (see diagrams P 2, Q 2, compared with P 1, Q 1) curve forwards on themselves, and deepen the concavities behind them to each side of the sternum. Owing to the change in position of the ribs, their outer curves are throughout enlarged, and the posterior curves to each side of the spine are deepened (§§ 39. 40. 55). The spinal column is pushed more and more backwards from the first to about the sixth or seventh dorsal vertebra, and less to the first lumbar. The

posterior curves of the six or seven inferior ribs are deepened relatively to the spinal column, as is evidenced in diagram O 2, inspiration, compared with diagram O 1, expiration, in which the spines of the lower dorsal vertebræ are more concealed in the former than the latter by the posterior curves. The posterior curves of the diaphragmatic set of ribs are deepened more than those of the intermediate set, while those of the thoracic set, excepting the fifth rib, are not deepened at all; the whole of the backward thrust of those ribs being spent in pushing back the spinal column. The twelfth rib does not move backwards so far as the eleventh, hence there is not here the usual gliding motion of the lower rib on the upper. Each rib has its own peculiar difference in curves and surfaces fitting it for its precise place, all the ribs combining, by change in position, to present one set of curves and surfaces in expiration, another in inspiration.

The five superior ribs (the thoracic set) form as it were the dome and upper portion of the chest. On expiration, when the space they inclose is every way narrowed, the profile of the upper edge of each rib is concave (diagrams P 1, O 1, and fig. XIV. a.), the inner concavity is shallowed (diagram Q 1), and the oblique surface tends to the

Diagram representing the position of a rib in expiration and in inspiration.



P 1.2. Side views.

Q 1.2. Views looking as it were down into the chest, a transverse section.

Q 3.4. Front views.

vertical direction (see diagram R 1). On inspiration, when the dome and upper part of the chest are amplified in every direction, the profile of the upper edge of each rib is nearly straight (diagrams P 2, O 2, and fig. XIV. b.), the inner concavity is deepened (diagram Q 2), and the direction of the oblique inner surface becomes more nearly horizontal (diagram R 2).

On expiration, the sixth rib, or the upper of the intermediate set of ribs, is curved upwards, while the seventh is curved downwards. On inspiration, these two ribs move further apart, they each of them become parallel and assume an almost straight profile. The eighth or lowest of the intermediate set, and the ninth or uppermost of the diaphragmatic set of ribs, are on expiration curved downwards like the seventh, and like it they become more nearly straight on inspiration. The anterior ends of the sixth, seventh and eighth ribs, or the intermediate set, being linked together, are raised on inspiration exactly to the same extent, while the lateral portions of the seventh and eighth ribs are not so much elevated as is that of the sixth; the sixth being raised more, relatively, in the centre than at the anterior extremity, while the seventh and eighth are more raised at their anterior extremities than at the centre.

The curve of the profile of the ninth rib, or the first of the diaphragmatic set, is not so much lessened on inspiration as is that of the eighth, as the anterior extremity and centre of the ninth rib ascend to a proportional extent. The profile of the tenth rib is straight, while that of the two lower ribs is curved slightly upwards. The inner surfaces of the lower ribs, which in expiration are somewhat oblique, the obliquity looking upwards, take a vertical direction on inspiration.

§§ 81–95. *Muscular actions.*

81. The great complication of the movements of the ribs in respiration is of course met by like complication in the actions of the muscles that move those ribs.

82. *The scaleni raise the first and second ribs and lower and bring forward the cervical vertebræ. See § 72.*

The scaleni act to elevate the first and second ribs during the whole of an inspiration; their action may be easily felt by placing a finger on each side of the neck, above the clavicles; the fingers are gradually pushed outwards and further away from each other during the whole inspiration. While the scaleni act from the cervical vertebræ to raise the first rib, they, in turn, also act from the first rib to draw downwards and forwards the cervical vertebræ, § 72. This movement of the cervical vertebræ is not absolute but relative, for they, riding on the dorsal vertebræ, are carried backwards by the inspiratory movements of the latter; but the backward movement of the dorsal is considerably greater than that of the cervical vertebræ; the latter indeed move forward relatively to the former, carry the origins of the scaleni more directly over the points of the ribs on which they act, and increase the dorsal arch. In the difficult breathing of persons suffering from chest disease, I have seen the head and neck move forwards on each inspiration.

83. *The scaleni expand the cervical portion of lung. See § 71.*

In Man a considerable portion of lung is situated above the clavicles; the expansion of this portion of the lung is effected, as it is in the Porpoise (see § 71), by the

mutual action of the scaleni and first rib on each other; while they raise the rib, the rib moves outwards and carries with it the scaleni; the scaleni then widen the space into which the lung rises and which they bound.

84. *Pleural scalenus**.

In addition to the ordinary scaleni, there is usually a special scalenus to expand the summit of each lung. This pleural scalenus arises from the transverse process of the seventh cervical vertebra, becomes tendinous and aponeurotic, and is inserted by a funnel-like tendinous web into the whole circuit of the first rib. The pleural scalenus somewhat resembles the large funnel-like scalenus of the Porpoise, that enlarges the lung in the neck, § 71.


85. *Intercostal muscles*, Plate XXIX. figs. XIII. *a.b.*, XIV. *a.b.*, XV. *a.b.*

§§ 46.48.49.60.61.

The action of each intercostal muscle depends entirely on the movements of the rib into which it is inserted; as the thoracic set of ribs approach each other in front, while the diaphragmatic and intermediate sets recede from each other, we might have anticipated that the intercostal muscles between the former have different respiratory actions from those between the latter. We have already seen, in the lower Mammalia, how completely the actions of the intercostal muscles correspond with the motions of the ribs (§§ 48. 49. 60. 61.); we shall find the same correspondence in Man.

The external intercostals of the seven superior ribs (all the thoracic and two of the intermediate sets) are throughout inspiratory; they raise these ribs, make them to glide on each other towards the vertebræ (§§ 6.7), and push backwards, through the ribs, the vertebral column; those of the thoracic set, in addition, make the oblique inner surfaces of the ribs more nearly horizontal, as diagram R illustrates.

Diagram R.



The anterior or intercartilaginous portions of the superior five internal intercostals are all inspiratory (fig. XIII. *b*); they raise the costal cartilages and make them glide on each other towards the sternum; the four superior internal intercostal muscles are inspiratory anteriorly, where the ribs approach each other, and expiratory poste-

* Fig. XXVI. Archives of the Royal Society.

riorly, where they recede from each other; the rest of them are throughout expiratory; they depress the ribs, make the lower edge of each rib glide towards the vertebræ in relation to the upper edge of the rib below, and bring forwards the spinal column.

At the upper and anterior part of the chest, where the ribs approach nearer to each other, an inspiratory shortening of the fibres of the internal intercostal overweighs the usual expiratory action (fig. XIV. *b*). There the external and internal intercostal muscles act simultaneously in a diagonal direction. (See § 48, last portion of it.)

The four inferior external intercostals inserted into the diaphragmatic set of ribs, are expiratory between the anterior and lateral portions of the ribs, where they are so far apart from each other as to overweigh the inspiratory gliding motion of the ribs towards the vertebræ, figs. XIII. *b*., XIV. *b*. (§ 49). Posteriorly near the spine they are all, save the lowest, inspiratory. See diagram M, fig. XV. *b*. The fibres inserted into the ninth costal cartilage cause it, during inspiration, to glide downwards and backwards on the cartilage above; so that the anterior or intercartilaginous fibres of the eighth external intercostal are inspiratory, while the lateral fibres between the ribs are expiratory, and the posterior fibres are inspiratory (figs. XIII. *b*., XIV. *b*., XV. *b*).

The seventh external intercostal, that of the lowest of the intermediate set, has its anterior fibres slightly shortened on expiration; its posterior, on inspiration. The whole of the lower internal intercostals are throughout expiratory, whether between the ribs or the cartilages; they make each lower cartilage glide forwards and upwards on the cartilage or rib above.

86. *Levatores costarum*.

The levatores costarum, which are nearly allied, almost identical, with the external intercostals, are all inspiratory; they elevate the ribs posteriorly, and the inferior muscles draw backwards and deepen the posterior curves of the ribs. See diagram B, § 9. The superior levators are but insignificant; the ribs on which they act, although they are raised considerably, have no backward movement. The six or seven lower levators are of considerable size; the ribs on which they act, though they are raised but little, are drawn backwards considerably (fig. XV. *a.b*). See § 50.

87. *Serratus magnus, chiefly expiratory*. See §§ 51. 63.

The serratus magnus, and the serratus posticus inferior, are the only other muscles besides the external and internal intercostals, that have, in some portion of them, an inspiratory, in others, an expiratory action. In the Dog (§ 63) and Ass (§ 51) the superior fasciculi of the serratus magnus are expiratory; the inferior are inspiratory; and the central fibres are neutral.

In Man the greater portion of the fasciculi of the serratus magnus act visibly in violent expiration. Indeed, from the direction of the superior fasciculi, they must be

expiratory*; the two or three lower fasciculi, from their direction, probably act in deep inspiration; but I have not observed them to do so.

88. *Serratus posticus inferior, expiratory.* See §§ 53. 64. 65.

In the Ass (§ 53) the four lower fasciculi of the serratus posticus inferior are inspiratory, the two upper expiratory, and the two intermediate neutral. In the Dog (§ 64) all the fasciculi are expiratory, while in the Rabbit (§ 65) they are all inspiratory. From the direction of the fibres, and from the fact that the fibres are shorter when the lungs are flaccid than when they are distended, I infer that in Man the serratus posticus inferior is expiratory.

89. *Inspiratory muscles, ordinary respiration.*

I have observed the following muscles to be inspiratory. In ordinary inspiration, the levator anguli scapulæ draws the scapula upwards away from the ribs so as to allow them unembarrassed play. The serratus posticus superior (I have seen it act in the Dog and the Ass) draws upwards and outwards the superior ribs into which it is inserted.

90. *Deep or difficult inspiration.*

In deep or difficult inspiration, the superior fibres of the trapezius assist to elevate the scapula.

The sternum is raised by the sterno-cleido-mastoid and by the sterno-hyoid and thyroid muscles; the origins of the latter take their bearings from the inferior maxillary bone, through the active intermedium of the genio-hyoid and the anterior belly of the digastricus.

The pectoralis minor and the lower fibres of the pectoralis major raise the ribs to which they are attached.

91-94. *Muscles of expiration.*

91. In addition to the intercostal muscles, the greater portion of the serratus magnus, and I believe the serratus posticus inferior, the following muscles act during expiration (I have seen them act in the Dog and Ass, §§ 51. 53. 54. 63.).

92. *Expiratory muscles acting on the scapulæ.*

The latissimus dorsi.—I have seen it act in Man in difficult expiration, especially in coughing, and I have also noticed it act on expiration in the Dog; it never contracts under any circumstances in inspiration. The latissimus draws the scapula forcibly downwards on the ribs; it is antagonist to the levator anguli scapulæ.

In coughing, the latissimi are assisted in their action on the scapulæ by the pectoralis major and the lower fibres of the trapezius; at the same time, while the serratus

* See QUAIN'S Plates of the Muscles, Pl. XIII.

magnus is in action, the rhomboidei will doubtless draw the scapula backwards. Through the combined actions of these muscles the upper part of the chest is compressed by the scapulæ.

In violent coughing and in epileptic fits, many of the muscles of the limbs act with great power.

93. *Expiratory muscles acting on the ribs.*

The recti draw down the sternum, and with it the annexed costal cartilages and their ribs.

The external oblique draw downwards the eight inferior ribs, bring forwards and downwards the posterior portions of the ribs, and compress the abdomen.

The internal oblique draw downwards and backwards the anterior extremities of the inferior ribs and their cartilages, and compress the abdomen.

The two oblique muscles, the external and internal, combine to pull downwards the lower ribs; the external oblique draws the posterior curves of the ribs forwards, the internal oblique draws the anterior portions of the ribs and the cartilages backwards.

94. *The triangulares sterni and the transversales combine to form one large muscle, the constrictor of the chest and abdomen. See §§ 68. 73.*

We have already seen that the transversales combine with the triangulares sterni to form one vast constrictor of the chest and abdomen in the Porpoise, the Dog, the Seal and Otter.

I find that the transversales and triangulares sterni combine in like manner in Man; these muscles are indeed perfectly continuous and form one web*.

The combined transversales and triangulares sterni may be described as one muscle; the constrictor of the chest and abdomen, arising from the two lower thirds of the sternum, the xyphoid cartilage, and the linea alba, and inserted into all the ribs, except the first, close to their cartilaginous attachments. The fibres of this vast web combine to narrow the space between all the opposite ribs; they cause the costal cartilages connected with the sternum to bend on the ribs and on themselves; they constrict at once the space between the thoracic, intermediate and diaphragmatic sets of ribs, and indeed the whole chest and abdomen.

The combined actions of the recti, the external and internal oblique, and the transversales compress the abdominal viscera, and thrust them upwards against the diaphragm so as to elevate it.

The sacro-lumbalis and the longissimus dorsi act with the quadratus lumborum to draw downwards the posterior portions of the ribs.

We have then a very powerful array of expiratory muscles; they are much more powerful than the inspiratory, as I previously inferred, and as has been proved by

* Fig. XXVI. Archives of the Royal Society.

Mr. HUTCHINSON, whose ingenious inquiries have thrown much light on the mechanism of breathing.

In every act of violent exertion, in lifting weights, in coughing, laughing and crying, in the violent convulsive fits of epilepsy, and in many other energetic acts, the vocal chords are forcibly closed by muscular actions; the air cannot be expired, and the expiratory muscles all combine in the attempt to force out the air from the lungs, but ineffectually till the vocal chords are separated. The muscles of the limbs have an admirable fixed point for the centre of their actions, when the chest is rigid with this violent but ineffectual straining at an expiration.

95. *The diaphragm.*

It is not my intention in this paper to describe minutely the form and respiratory actions of the diaphragm; but this muscle must not be passed over, as it plays so important a part in the breathing machinery, and modifies so much the form, the number and the movements of the lower set of ribs, or those that assist in diaphragmatic respiration.

I have seen the action of the diaphragm in the Dog, the Ass, the Rabbit, and the domestic Fowl. The form and position of the diaphragm depend entirely on the relative proportion of the lower and posterior, or diaphragmatic, to the upper and anterior, or thoracic portion of the lung.

In the Ass, the upper or thoracic portion of lung is very narrow and has but little play; the diaphragmatic portion is of great bulk and expansibility posteriorly; there is but a small extent of lung anteriorly. The diaphragm is very oblique, tending to the vertical direction; its anterior fibres are strong but short; its lateral fibres are long; they are inserted into an oblong central tendon. When the diaphragm acts, the diaphragmatic portion of the chest is expanded behind and to the side. The body and lower or posterior portion of the diaphragm moves forwards and downwards to a great extent, the anterior portion descends very little, and the whole muscle becomes comparatively flattened, § 35.

In the Dog, the upper or thoracic portion of the lungs is much expanded on inspiration; the lower surfaces of the lungs and the diaphragm are almost horizontally concave. The diaphragm has long muscular fibres anteriorly; its descent being almost as great anteriorly as posteriorly, § 35.

In Man, the diaphragm is oblique, approaching the horizontal direction. The right side is larger and bulges higher into the chest than the left. From the floor of the pericardial sac is given off a strong tendinous web that sheaths the whole pericardium and is inserted into the investments of the great vessels at the upper part of the chest. A thin aponeurosis ascends over each pleura, another descends on the peritoneum. A strong tendinous sheath rises from the central tendon, surrounds the vena cava hepatica, and invests all its branches. On inspiration, the bulges of the diaphragm are first flattened, and then the whole muscle descends to a nearly equal

extent. The central tendon in its descent stretches and elongates the pericardial sac, increasing the space containing the heart. When the diaphragm is forced up by the contraction of the abdominal muscles, the tendinous fibres with which it invests the vena cava, interstitially support the mass of the liver.

96-100. *Varieties in the mechanism of respiration in the human subject due to age and sex.*

96. In the human subject the extent of the lung varies with the age and sex of the individual. In the adult well-formed man, the chest is apparently of greater bulk than the abdomen. The proportion of the chest to the abdomen is greater in the active than the inactive.

97. *Female*.*

In the female the development of the abdomen in relation to the chest is considerably greater than it is in man. Owing to the tightness with which the stays are usually worn round the lower or diaphragmatic portion of the chest, the diaphragm is compressed and its inspiratory expansion is greatly impeded. The opposite conjoint cartilages of the sixth, seventh and eighth ribs (the intermediate set) are pressed nearer to each other, so that instead of forming an angle with each other, they become almost parallel. To make amends for the artificial impediment to respiration of the diaphragmatic portion of the lungs, the thoracic portion is unnaturally developed.

98. *Fœtus† and new-born infant‡.*

In the child§, and still more in the fœtus and new-born infant, the abdomen and its viscera are very large in proportion to the chest and its contents. While the lungs are small, the liver is of great size.

In the fœtus, the unexpanded lungs occupy a very small space; the sternum and costal cartilages fall inwards and form a hollow; the angle between the opposed sixth, seventh and eighth costal cartilages below the sternum is obtuse, and the abdominal viscera push outwards the inferior ribs to a very great extent.

In the new-born infant the sternum and costal cartilages, by virtue of their elasticity and of muscular actions, move forwards, and from being concave become flat or slightly convex; the sixth, seventh and eighth cartilages form with each other a right angle.

Influence of the elasticity of the walls of the chest on the first inspiration and on respiration.

The inspiratory expansion of the chest in the new-born infant illustrates well the effect of the elasticity of the thoracic walls in maintaining a considerable portion of

* Fig. XIX. Archives of the Royal Society.

† Fig. XXIV. Archives of the Royal Society.

‡ Fig. XXV. Ibid.

§ Fig. XXI. XXII. Ibid.

air in the lungs. By no muscular effort can a child that has once breathed force out the whole of the air from its lungs. If we compress the chest after death, a portion of air is pressed out through the trachea; on removing the pressure the resiliency of the walls of the chest draws as much air into the lungs as was previously expressed; an incomplete but artificial inspiration can thus be performed. A very simple apparatus, acting on this principle, is recommended in the Humane Society's Report for 1834, p. 126. The chest is compressed by a many-tailed bandage, the tails of which cross each other; when they are alternately tightened and relaxed they excite artificial respiration. A syringe has been constructed to act on the same principle; after it draws a portion of air out of the lungs through the trachea, fresh air, being admitted, rushes in to supply its place; in both these cases the lungs are expanded by the elasticity of the parietes of the chest.

I conceive that respiration after the first breath is essentially performed by muscular actions; at the end of each expiration the elasticity of the walls of the chest will tend to commence the next inspiration; until the walls of the chest arrive at the medium size, or that which they retain after death, the elasticity will act along with the muscles; as soon as they have passed beyond this point, the elasticity will tend to act against the muscular actions; indeed these have to overcome the elasticity. At the end of an inspiration, elasticity will commence the expiration, assist in the action up to the neutral point, and resist it beyond that point. Thus elasticity as an agent in respiration balances itself.

I would not have remarked on the elasticity of the walls of the chest as a respiratory agent, but for a short note from Mr. HUTCHINSON, informing me that he was inquiring into the subject. From the success of his previous inquiries I look forward to his communication with much interest.

99. *The child**.

In the child, the liver and the stomach, and other abdominal viscera push the diaphragmatic set of ribs and the cartilages of the intermediate set forwards and outwards, and cause them to project beyond the thoracic set of ribs, as the girth of the abdominal organs is considerably greater than that of the thoracic. When the diaphragm descends, the lungs and heart occupy the place previously taken up by abdominal viscera, and as the lungs are smaller than the viscera they replace, the lower end of the sternum and xyphoid cartilage, the conjoint cartilages of the sixth and seventh ribs, and the sixth rib fall backwards on inspiration owing to the pressure of the atmosphere. If the inspiration be so deep as to bring the lungs down to the lower edge of the floating cartilages, all those cartilages fall backwards also, and those of the opposite side approach each other.

As the proportion of the abdominal to the thoracic viscera lessens as life advances, the lower cartilages gradually cease to fall backwards during inspiration, and after-

* Figs. XXI. *a.b.*, XXII. *a.b.* Archives of the Royal Society.

wards, as the proportion of the thoracic to the abdominal viscera increases, a forward movement of the lower cartilages takes place ; this gradually increases until, in adult life, the forward movement of the conjoint cartilages and of the lower portion of the sternum is even greater than that of the superior cartilages and the upper portion of the sternum.

100. *Old age**.

In the aged, the costal cartilages being ossified, each rib and cartilage forms as it were one inflexible bone ; the costal cartilages still hinge on the sternum. The costal respiration is performed by the elevation and consequent variation in the position of the curves of the ribs. There is no yielding of the cartilages, consequently the lower part of the sternum and the conjoint costal cartilages are pushed forward to a greater extent than they are in the youthful. The thoracic respiration, though considerable, is not so great as in the adult or young man ; to make amends, diaphragmatic respiration is increased, and the angle formed between the opposite costal cartilages below the sternum is more open. The old man does not require the energetic breathing of the young. The bulk of the lung increases, the air-cells being enlarged, in the aged, and the chest gradually takes on more and more the form that it has on an ordinary or even a deep inspiration ; consequently the movement of the ribs on inspiration is not so great in the old man as it is in the middle-aged. The increase of the dorsal arch due to the permanent inspiratory form, causes the stooping, and, in part, the shortening of the aged.

101. *Varieties in respiratory movements induced by disease.*

Permit me to hint at the influences of some diseases of the lungs on the respiratory movements of the chest.

If the larynx be narrowed so as to permit but little air to enter the lungs, the diaphragm descends so rapidly that the air has not time to fill up those portions of the lungs displaced downwards by the diaphragm ; the consequence is that the pressure of the atmosphere forces backwards and inwards the costal walls on the lungs.

If the summit of the lung be affected with phthisis, the corresponding portion of the chest is but little dilated, and the ribs are depressed and almost motionless over the diseased portion of lung ; sometimes the rib even falls in at the beginning of inspiration.

In inflammation of the lower lobe of the lung, that lobe is distended by diseased secretions ; the chest over it is permanently expanded and has little or no respiratory movement ; at the same time the upper portion of the same side of the chest is less actively inspiratory.

If the diaphragm be inflamed on one side, that side does not act ; the diaphragmatic ribs and the hypogastric region do not move forwards on the affected, though they do on the healthy side.

* Fig. XXIII. *a.b.* Archives of the Royal Society.

If any part contiguous to the ribs, on one side, would be injured by the respiratory motion of those ribs, then that side of the chest is often motionless, though the lung be sound.

If the air-cells be dilated, the whole chest takes on permanently the form that it has on a deep inspiration.

These instances show the practical value of a thorough knowledge of the healthy respiratory movements of each portion of the chest; the attention is at once called to any point that, owing to disease, has not its due motion.

The above paper relates almost exclusively to the mode in which the movements of the ribs expand and contract the chest in respiration; the diaphragm is only treated of incidentally. The remarkable series of respiratory movements that take place in the nostrils, lips, mouth, palate and tongue, in the larynx and pharynx, and in the cervical fasciæ, are not even mentioned.

On a future occasion I hope to investigate those parts of the mechanism of respiration that are here only briefly alluded to, or altogether omitted.

SUMMARY.

Demonstrative proof of the statements in the following summary is, I believe, advanced in the preceding paper and its accompanying drawings.

The Snake (§§ 3–11. Plate XXIII. figs. I. II.) has the most elementary form of ribs. They are all alike, and are only attached at their vertebral end, their anterior ends being free (§ 4). There are neither sternum nor costal cartilages.

When the lungs are expanded, the levatores costarum, and the external intercostals raise the ribs, widen the spaces between them, make their anterior ends move forwards, and cause the upper edge of one rib to glide backwards in relation to the lower edge of the rib above it. Diagram A 1.2, fig. I. *a.b.* §§ 4. 6. 7. 10. The scalenus acts on the first rib.

The levatores costarum draw the ribs backwards behind, outwards to the side. Diagram B 2, § 9.

When the lungs are emptied the movements of the ribs are exactly reversed by the long depressors of the ribs, and by the internal intercostals and the transversalis. Diagram A¹, B¹, §§ 6, 11.

In Birds (§§ 17–27. Plate XXIV. XXV. figs. III.–VI.) a sternum and sternal ribs are coupled with the vertebral ribs and vertebræ to complete the circuit of the chest (§ 17).

The respiratory movements, and the muscles exciting the movements of the sternal ribs on the sternum and on each other, are exactly the same in principle, though reversed in direction with those of the vertebral ribs on the vertebræ and on each

other. Diagram C 1.2, figs. VI. *a.b.* § 18. On inspiration, the angles between the vertebral and sternal ribs become more open; the sternum moves forwards and the spinal column slightly backwards, and the chest is slightly expanded. These movements are effected by the combined action of the scaleni and sterno-costal muscles on the first vertebral and first sternal ribs respectively; of the levatores costarum and external intercostals on all the lower vertebral ribs; and of the sternal intercostals on all the lower sternal ribs. §§ 19. 20. 23. 24. fig. VI. *b.* diagram C 2.

On expiration, the movements are reversed by the internal intercostals, the external and internal oblique, recti, transversales, and other muscles. § 26, fig. VI. *a.* diagram C 1.

In the Mammalia (§§ 28–100. Plates XXVI.–XXIX. figs. VII.–XV*.) the addition of a large and efficient diaphragm—that in the Bird is small—modifies the form and varies the movements of the ribs and actions of the muscles in different parts. The ribs articulate with a dorsal arch (§ 31. X. *c.*); they vary in length, those hinging on the centre of the dorsal arch are the longest; while those on the superior curve gradually shorten from below upwards; those on the inferior curve shorten from above downwards. Diagram D 1.2. O. 1.2. figs. XIV. *a.b.* §§ 31. 32. 33.

By virtue of this arrangement, the ribs, articulating with the superior curve, when they are raised, approach each other anteriorly. These ribs have each a cartilage articulating with the sternum, that is analogous to the sternal rib of birds; they comprise the thoracic set. § 34. 35 Ass, §§ 67 Dog, 79 Man.

The ribs that hinge on the inferior curve of the dorsal arch, when raised, recede from each other; they have floating cartilages, and are the diaphragmatic set of ribs. §§ 34. 35. 67. 79.

Intermediate are the longest ribs connected with the dorsal arch; their cartilages are usually linked together and articulate with the lower end of the sternum; they, when raised, usually recede slightly from each other. Diagram N², fig. XIII. *b.* All the ribs recede from each other behind (Diagram M², fig. XV. *b.*). The anterior portions of the ribs move forwards and upwards, and carry with them the costal cartilages and the sternum (O. 2. fig. XIV. *b.*). The posterior portions of the ribs move backwards, push backwards the vertebræ, and deepen the dorsal arch. Diagram O, fig. XIV. *b.*

The scaleni invariably act during the whole time of an inspiration (§§ 47. 58. 82); and in Man and the Porpoise they expand the portion of lung in the neck (§§ 71. 83), assisted in Man by the pleural scalenus (§ 84). They do not draw the cervical vertebræ to either side, but they draw them, during inspiration, forwards and downwards (§§ 72. 82).

The external intercostals between the thoracic set of ribs are throughout inspiratory (§§ 48. 60. 85); those portions between their cartilages are expiratory (§ 60); between the diaphragmatic set of ribs they are inspiratory behind, expiratory to the side and in

* And numerous additional drawings in the Archives of the Royal Society.

front; and between their cartilages they are inspiratory (§§ 49. 60. 85); between the intermediate set of ribs they are for the most part slightly inspiratory between the ribs, and expiratory in front between the cartilages (figs. XIII. *a.b.*, XIV. *a.b.*, XV. *a.b.*).

The internal intercostals of the thoracic ribs are expiratory behind and inspiratory in front, if the ribs approach there, and are inspiratory between their costal cartilages. Between the diaphragmatic and intermediate sets of ribs and between their cartilages, they are throughout expiratory (§§ 48. 49. 61. 85, figs. XIII.–XV.). The levatores costarum draw the posterior portion of the lower ribs backwards (§ 86, diagram B, fig. XV. *a.b.*).

In the Ass and Dog, the upper fasciculi of the serratus magnus are expiratory, the lower inspiratory, and the intermediate neutral (§§ 51. 63). In Man, the greater part of the fasciculi are expiratory (§ 87).

In the Ass, the lower fibres of the serratus posticus inferior are inspiratory and the upper expiratory (§ 52); in the Dog, and I believe in Man, they are throughout expiratory (§ 88).

The following muscles I have observed to be *inspiratory*, in addition to those named above:—

On a moderate inspiration, § 89.—

The levator anguli scapulæ;

The serratus posticus superior.

On a deep or difficult inspiration, § 90,—

The superior fibres of the trapezius;

The sterno-cleido mastoid;

The sterno-hyoid and thyroid, with the genio-hyoid and digastricus;

The pectoralis minor;

The pectoralis major, its lower fibres.

The following muscles I have observed to be *expiratory*, in addition to those named above (§ 93. 94).

The latissimus dorsi draws down the scapula in coughing; the trapezius, its lower fibres, the pectoralis major and the rhomboidei (inferred) combine with the latissimus dorsi and the serratus magnus to draw the scapula forcibly downwards and forwards on the ribs. The recti and the external and internal oblique draw downwards the sternum and the ribs; the external oblique draw the posterior portion of the ribs forwards, the internal oblique their anterior portions backwards.

The transversales and the triangulares sterni combine together to form one muscle, *the constrictor of the chest and abdomen* arising from the sternum, xyphoid cartilage and linea alba, and inserted into all the ribs but the first (§§ 68, 94); in the Porpoise it rises into the neck, and is inserted into all the ribs. § 73.

The sacro-lumbalis and the longissimus dorsi.

The expiratory muscles are, combinedly, more powerful than the inspiratory.

Fig. I.
Snake.

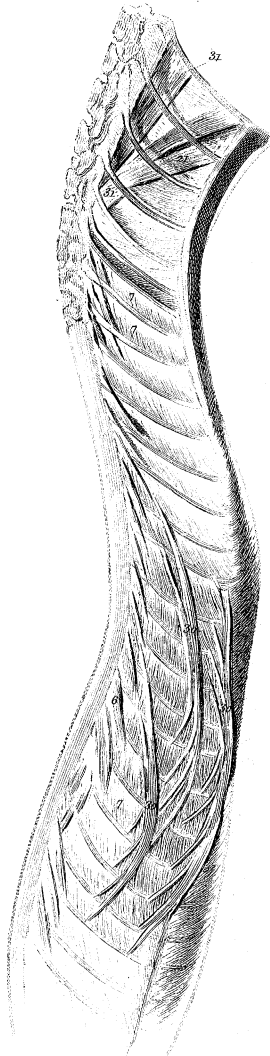


Fig. II.
Chameleon.

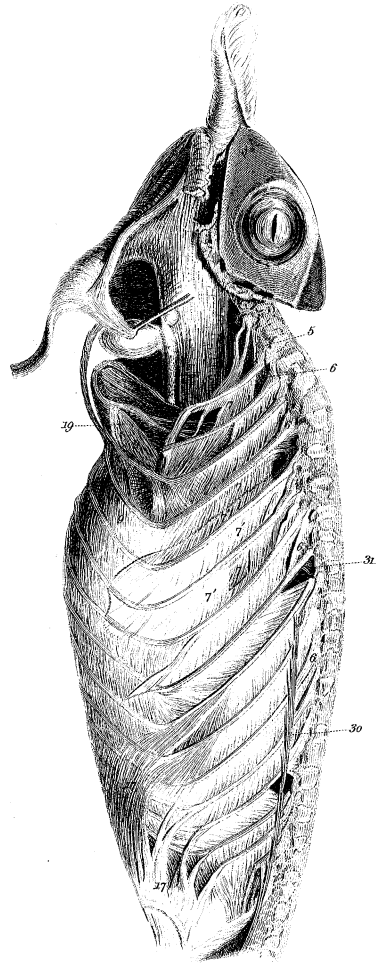
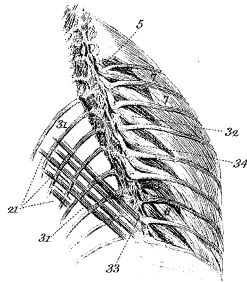


Fig. I b.



Fowl.

Fig. III a.

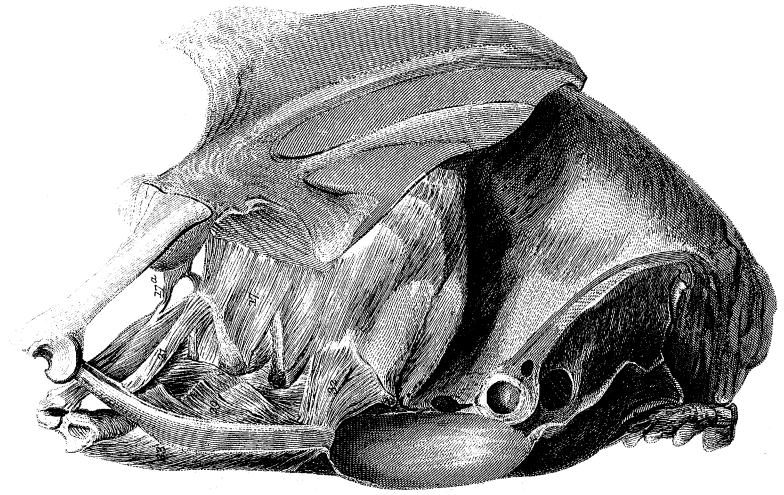


Fig. III b.

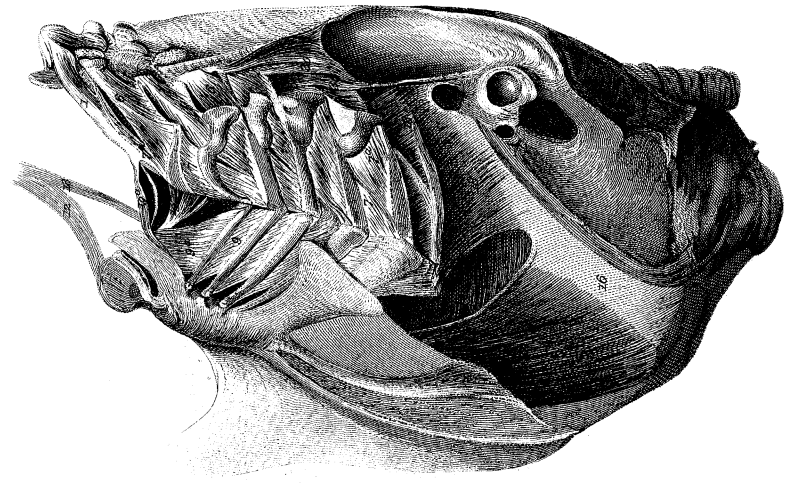
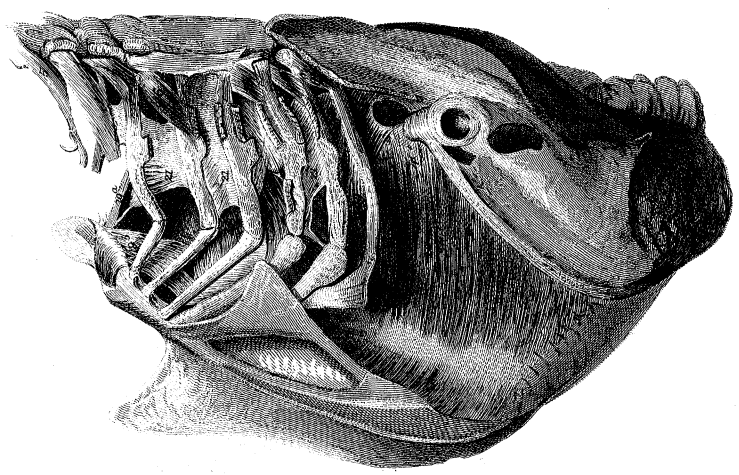


Fig. III c.



Swan

Fig. VI. a.
Expiration.

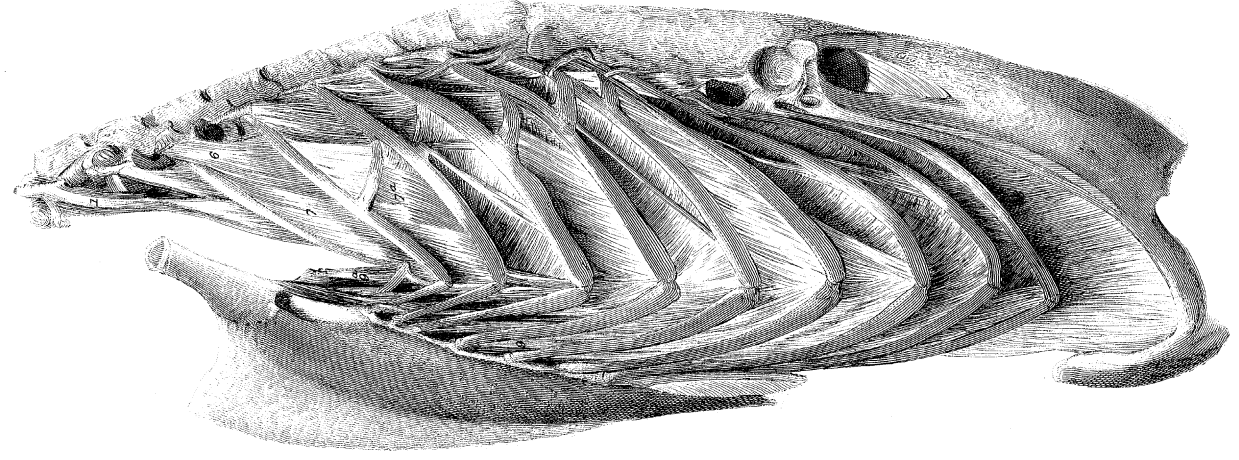


Fig. VI. b.
Inspiration.

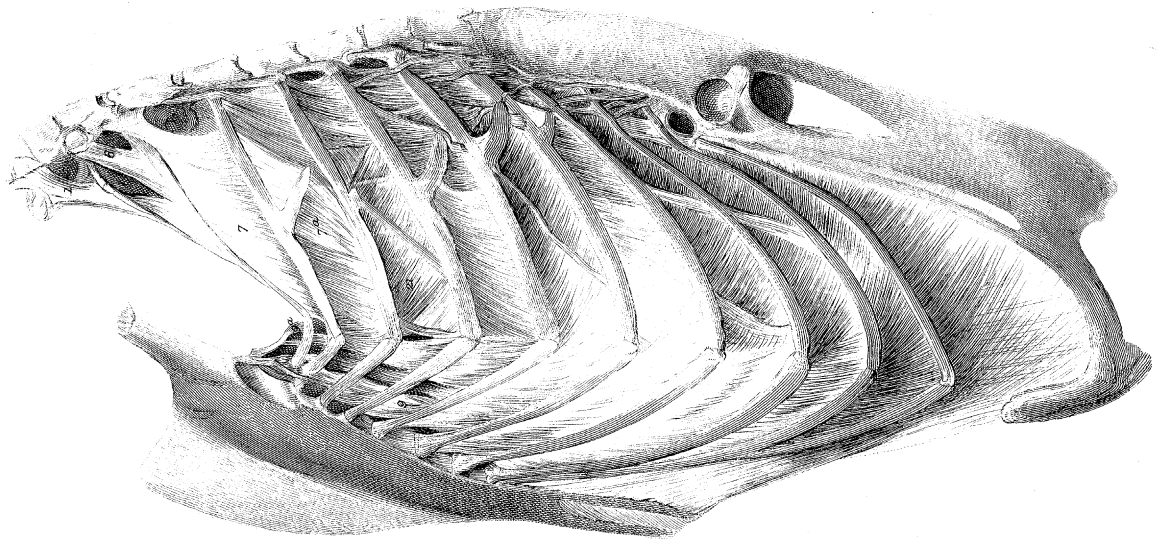


Fig. IV.
Hawk

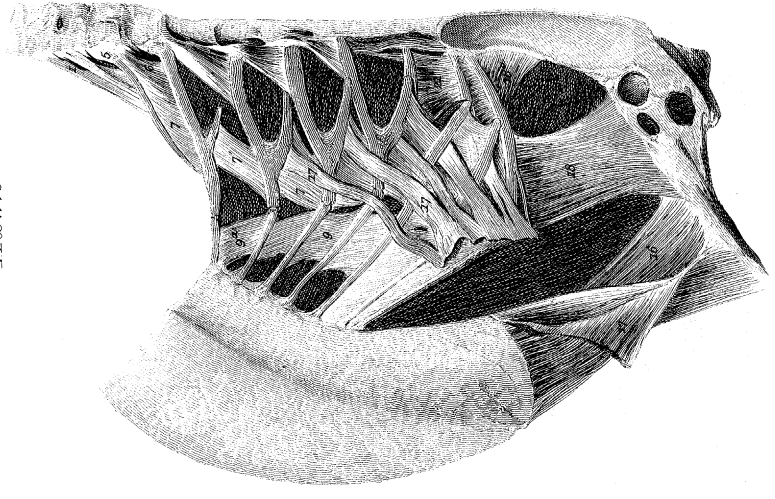
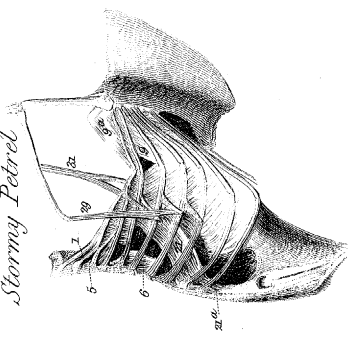
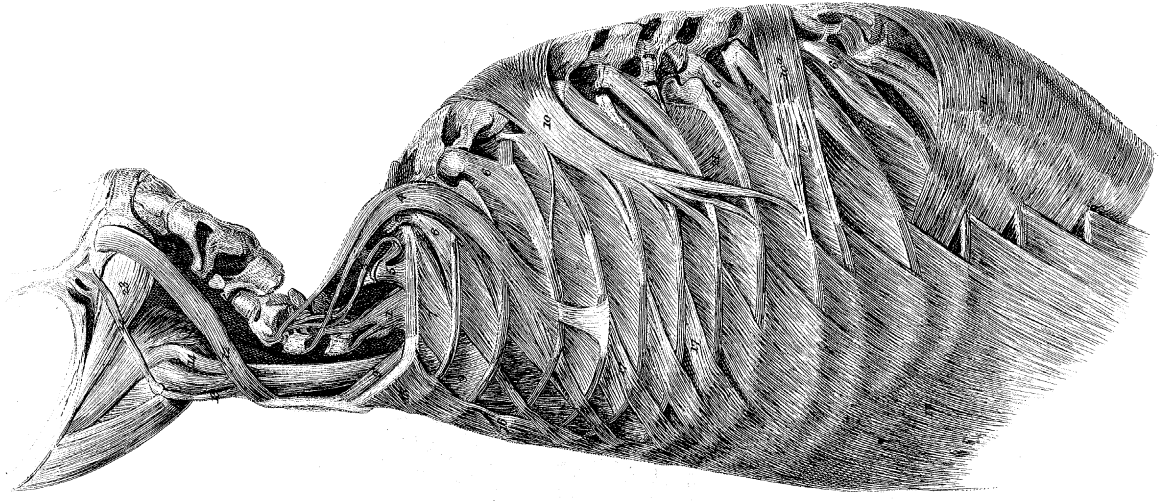


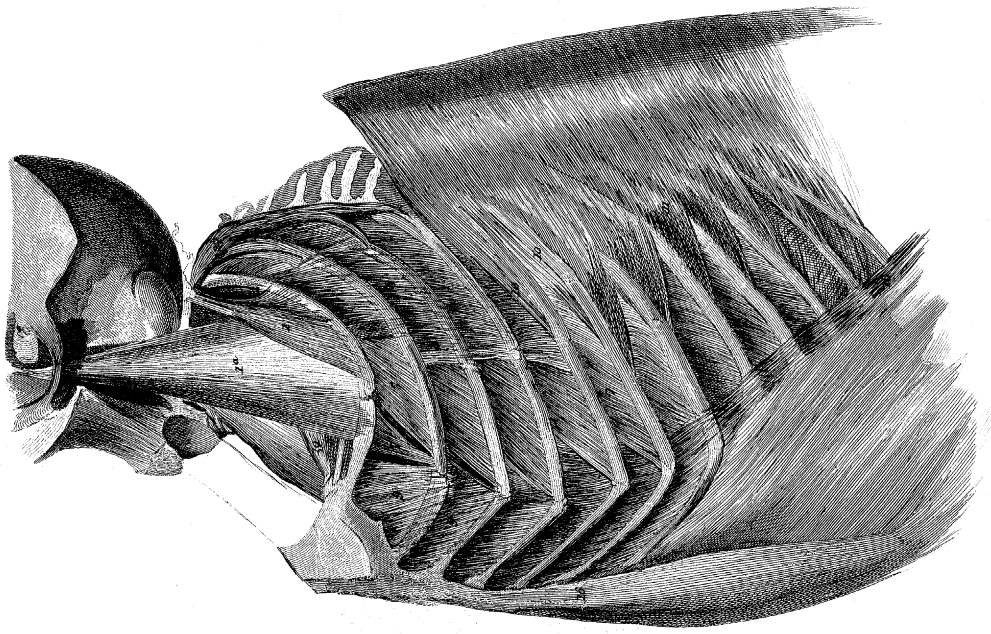
Fig. V.
Stormy Petrel



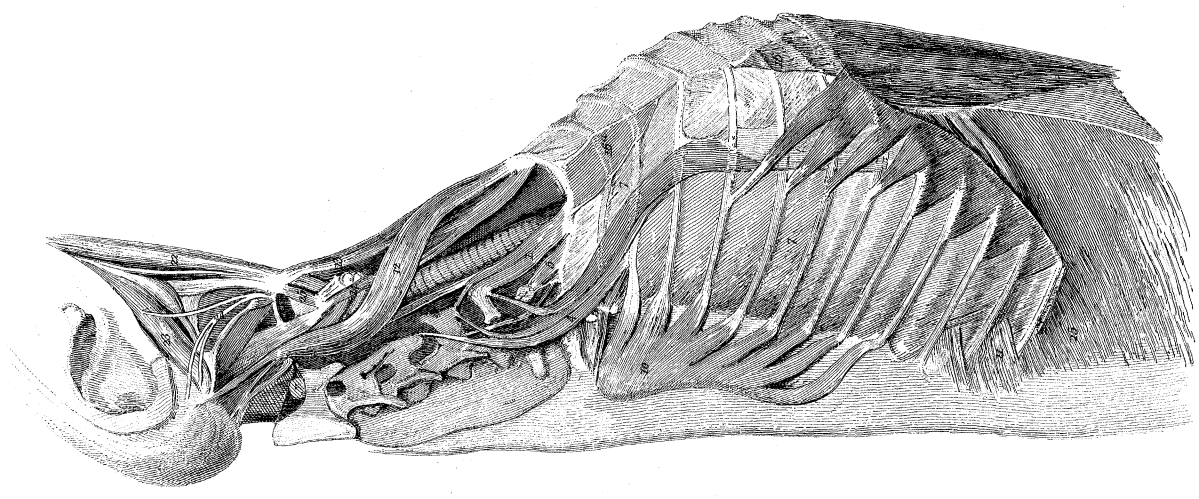
*Fig. VIII.
Seal.*



*Fig. VII.
Porpoise.*



*Fig. X.
Dog.*



*Fig. IX.
Calf.*

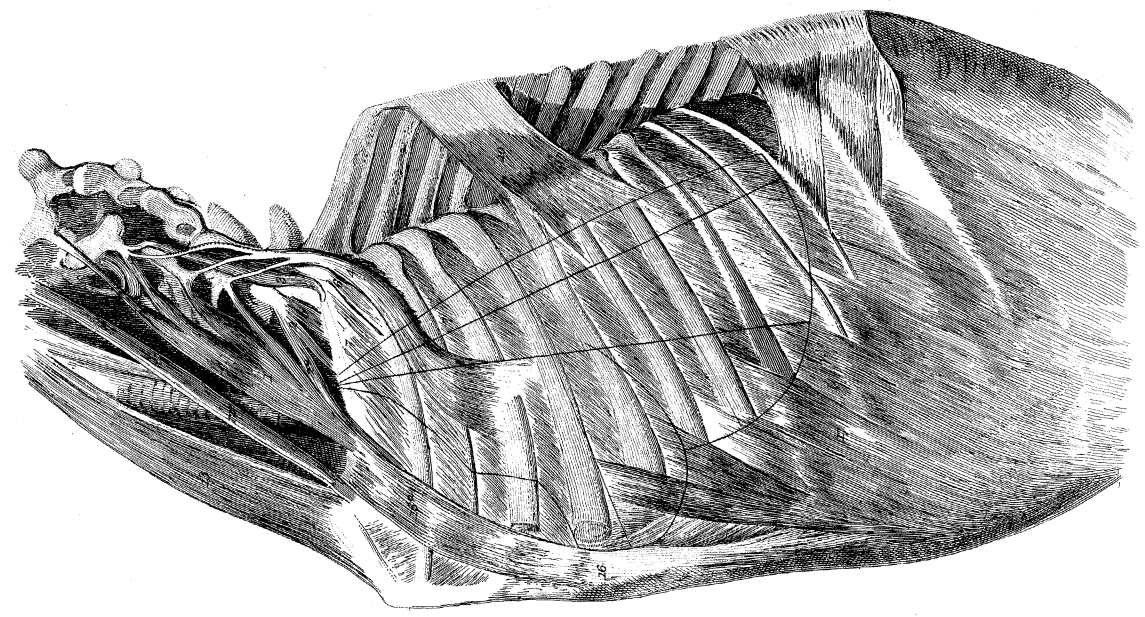


Fig. XI.
Rabbit.

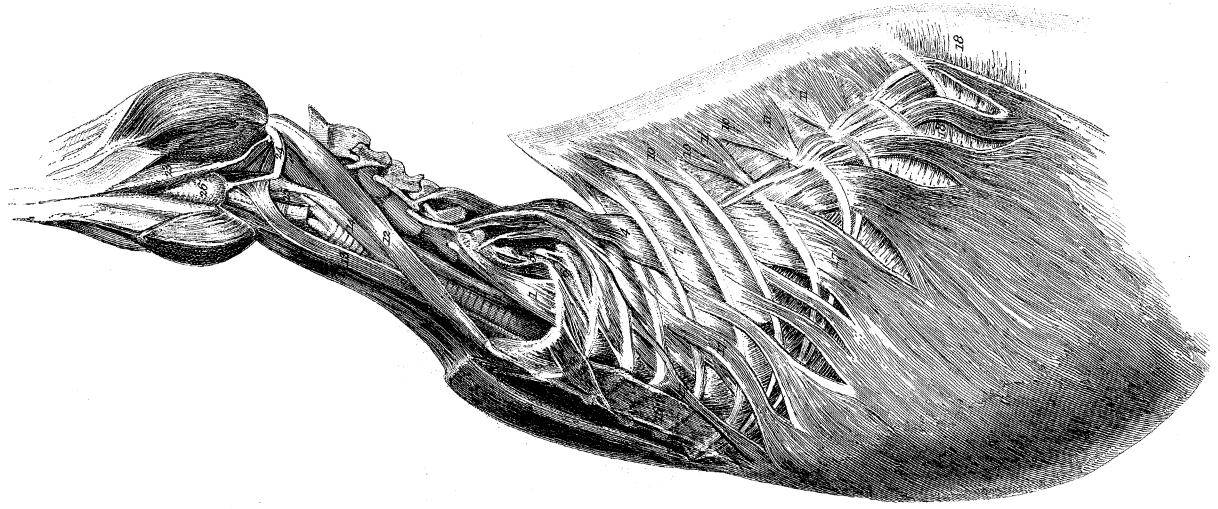
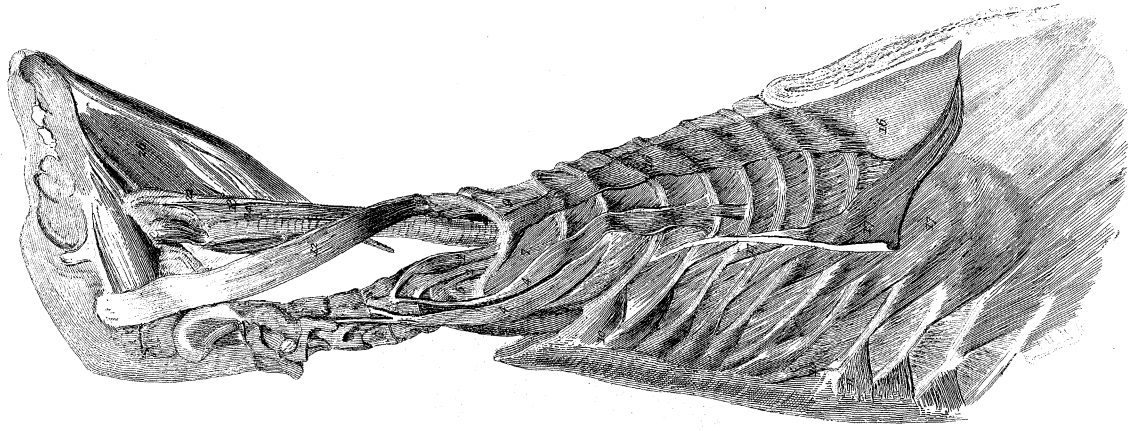


Fig. XII.
Otter.



Young Man.

Fig. XIII a.

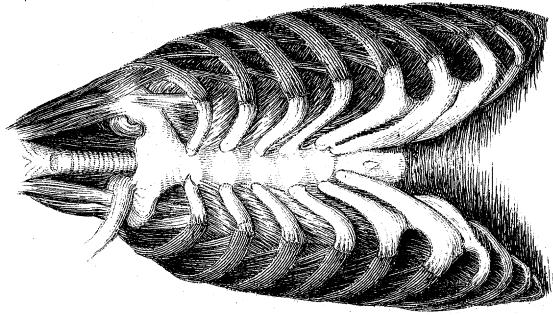


Fig. XIV a.

The Lungs flaccid as in Expiration.


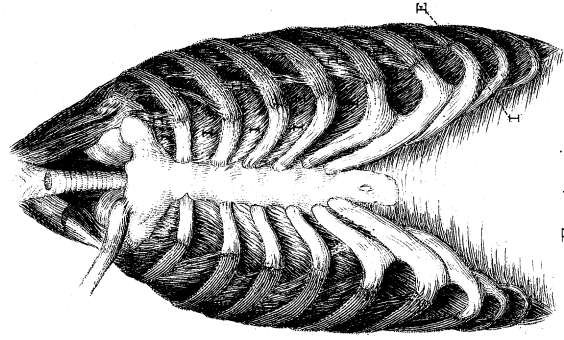



Fig. XIII b.



Front views.

Fig. XIV b.

The Lungs distended as in Expiration.



Side views.

Adult.

Fig. XV a.

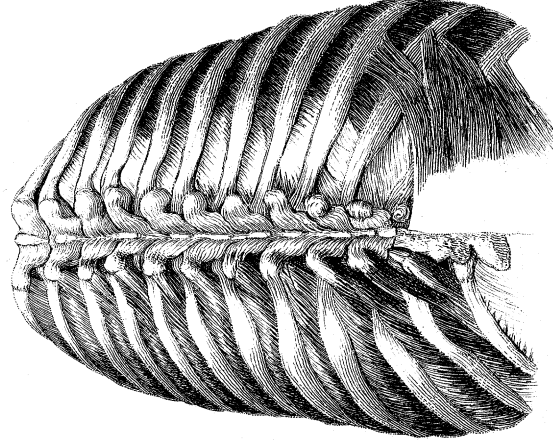
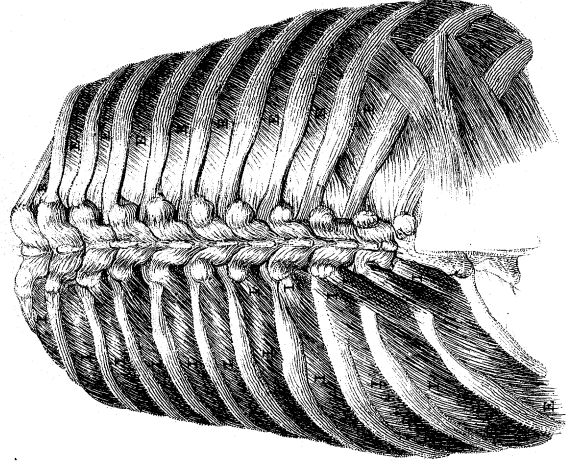


Fig. XV b.



Dorsal views.

Position of the Ribs and action of the Intercostal muscles in Expiration and Inspiration.

E. Expiratory muscles. I. Inspiratory muscles.

At first sight the opposite action of the different fibres of the same muscle seems contradictory and unnatural, but when we find that the ribs at the upper part of the chest approach, whilst those of the lower part recede from each other, and that the posterior portion of each rib moves backwards, while the anterior portion moves forwards, we admire the perfect subservience of the actions of the muscles to the motions of the ribs. We now wonder that the motion of the different ribs, and of the same rib in different parts, should be so opposite; but when we find that the motions of these ribs and of the diaphragm exactly correspond to the form and capacity of the lungs in different animals, and that the form and capacity of the lungs are in each exactly fitted to the habits of the animal, we feel that we have some insight into the most beautifully adjusted and harmonious piece of machinery that either art or nature has constructed.

DESCRIPTION OF THE PLATES.

The same figures denote the same parts in all the illustrations, both in the engraved figures and in the drawings deposited with the paper in the Archives of the Royal Society.

1. The Scalenus of the first rib, present in all, voluminous in the Porpoise (fig. VII.), trivial in the Seal (fig. VIII. §§ 10.23.47.58.71.72.82.83).

1 *a*. A scalenus of the first rib, peculiar to the Porpoise (fig. VII.), external to the large funnel-shaped scalenus (§§ 71.72).

1 *a*. In Man (fig. XIII. *b*.), a funnel-shaped scalenus of the first rib often exists, acting to expand the apex of the lung (fig. XXVI. Archives of the Royal Society) (§ 84).

2. A posterior scalenus of the first rib, present in the Otter, Calf and Rabbit (figs. XII. IX. XI.), and the Monkey (fig. XV. in the Archives of the Royal Society).

2 *a*. An additional insertion of No. 1. passes in the Calf (fig. IX.) to the second rib.

3. A posterior and external scalenus of the first rib, inserted near the head of the bone, external to the levator costæ, exists in the Calf and Dog (figs. IX. X.), and the Monkey and Ass (figs. XV. X. Archives of the Royal Society).

4. The long anterior scalenus to several ribs, exists in the Dog, Otter, Seal, Rabbit and Calf (figs. X. XII. VIII. XI. IX.), and in the Monkey (fig. XV. Archives of the Royal Society) (§§ 47.58).

5. The first levator costæ.

6. The levatores costarum (§§ 7.9.23.50.86).

7. The external intercostals (§§ 6.7.24.46.48.49.60.85).

7 *a*. In Birds (figs. III. VI.), portions of the external intercostals arise from the spurs (§ 23).

7¹. In the Chameleon (fig. II.) there are external intercostals, whose fibres are almost vertical, superficial to the usual external intercostals (§ 14).

7¹. In the Rabbit (fig XI.) a supracostal muscle passes from the seventh rib to the eighth, ninth and tenth ribs.

8.8 *a*. In the Porpoise (fig. VII.) a web of superficial fibres passes from the first and second to the third, fourth and fifth ribs (§ 74).

9. The portions of the internal intercostal muscles between the costal cartilages. In Birds (figs. III. VI.) the muscles between the sternal ribs are joined to those between the vertebral ribs (§§ 18.24). In the Porpoise and Calf (figs. VII. IX.), and the Monkey and Pig (figs. XV. VII. Archives of the Royal Society), the intercartilagenous portion of the internal intercostals are distinctly separated from the intercostal portions (§§ 48.49.61.85). In the Seal (fig. VII.) the first costal cartilage has a special elevator (§ 62).

9 *a*. 9 *b*. In Birds (figs. III. VI.) and in the Chameleon (fig. II.) triangular muscles arise from the sternum and are inserted into the sternal ribs (§§ 23.15).

10. The serratus posticus superior (§§ 52.64).

10 *a*. In the Seal (fig. VIII.) there is an intermediate serratus posticus (§ 64).

11. The serratus posticus inferior. In the Porpoise and Rabbit (figs. VII. XI.) the superior and inferior serrati are blended (§§ 53.64.65.75.88).

12. Sterno-mastoid (§§ 59.90).

13. Sterno-hyoid (§§ 59.71.90).

14. Sterno-thyroid (§§ 59.7.90).

15. In the Seal and Rabbit (figs. VIII. XI.) there is a depressor of the first rib arising from the sternum. In the Seal there are, in addition, depressors of the second and third ribs, which are indeed, with the depressor of the first rib, additional fasciculi of the external oblique (§ 67).

16. The rectus abdominis is inserted in the Otter and Rabbit (figs. XII. XI.) into the first rib (§ 67).

16 *a*. A depressor of the first rib, arising from the aponeurosis of the rectus, exists in the Dog and Calf (figs. X. IX.), and the Monkey and Ass (figs. XV. X. Archives of the Royal Society) (§§ 54.67).

17. External oblique (§§ 16.26).

17 *a*. In the Fowl (fig. III. *a*.) fibres of the external oblique arise from the sternum (§ 26).

18. The internal oblique (§§ 26.54.66.93).

19. Transversalis (§§ 11.16.26.54.60.73.94).

19 *a*. In the Fowl there are sterno-costal muscles to the 1st, 2nd and 3rd ribs (§ 26).

20. Sterno-costal muscles, or triangulares sterni (§§ 68.73.94).

The transversales and sterno-costals combine to form one muscle in the Mammalia (figs. XI. *b*. XII. *b*. XIII. *b*. XVI. *b*. XXVI. Archives of the Royal Society), and in a modified manner in the Fowl and Chameleon (figs. III. II.) (§§ 68.73.94).

21. The internal intercostals (§§ 48.49.61.85).

21¹. In the Chameleon and Snake (figs. II. I.) an infra-costal muscle passes from the upper edge of one rib to the rib but one above (§§ 11.16).

21 *a*. In the Hawk (fig. IV.) there is an infra-costal from the eighth to the sixth rib.

In the Stormy Petrel (fig. V.) a muscle acts from the pelvis on the lowest rib.

22.23.24. Digastricus, and its varieties.

In the Monkey and Ass (figs. XV. X. Archives of the Royal Society) the digastricus is two-bellied, as it is in Man; it is replaced in the Seal and Rabbit (figs. VIII. XI.) by two muscles arising from the mastoid processes inserted, one into the hyoid bone, the other into the lower jaw; and in the Dog (fig. X.) by one muscle to the lower jaw. The Porpoise (fig. XVI. *b*. Archives of the Royal Society) has a powerful genio-hyoid in lieu of the digastricus.

27. In the Porpoise (fig. VII.) a muscle passes from the cervical vertebræ to the ribs, resembling a scalenus (§ 74).

28. Omo-hyoid in the Monkey (fig. XV. Archives of the Royal Society).

29. In the Fowl and Stormy Petrel (figs. III. *a*. IV.) a muscle acts from the superior ribs on the scapula to raise it (§ 25).

30. The sacro-lumbalis is shown in the Ass (fig. X. Archives of the Royal Society). In the Chameleon and Fowl (fig. II. III.) an analogous muscle arises from the pelvis to be inserted into the ribs (§§ 16.26.54.66.94).

30. In the Snake (fig. I.) represents a series of muscles that pass from rib to rib and serve as muscles of progression (§ 3).

31. In the Stormy Petrel (fig. V.),

31 and 32, in the Fowl (fig. III. *a*.), are muscles acting from the scapula to raise the ribs during inspiration (§ 25).

31. In the Snake and Chameleon (figs. I. *a.b.*, II.), are muscles acting from the dorsal vertebræ to lower the ribs (§§ 11.13.16).

32. In the Chameleon (fig. II. *b*. Archives of the Royal Society) are muscles acting from the vertebræ on the ribs to narrow the chest (§ 16).

32.34. In the Snake (fig. I. *b*.) are muscles acting from the vertebræ on the ribs to raise them (§ 10).

33. In the Snake is a muscle passing from rib to rib near their vertebral articulations (§ 10).

PLATE XXIII.

Figs. I. *a.b.* (figs. I. *c.d.e.* Archives of the Royal Society). The muscles of respiration in the Snake (§§ 3-11).

Fig. II. (figs. II. *b.c.d.* Archives of the Royal Society). The muscles of respiration in the Chameleon (§§ 12-16).

PLATE XXIV.

Figs. III. *a.b.c.* Muscles of respiration in the Fowl (§§ 17-27).

PLATE XXV.

Fig. IV. Muscles of respiration in the Hawk (§§ 17-27).

Fig. V. Muscles of respiration in the Stormy Petrel.

Fig. VI. *a.* Muscles of respiration and ribs of the Swan, as they are on expiration.
The sternum is pushed as near as possible to the spine.

Fig. VI. *b.* Muscles of respiration and ribs of the Swan, as they are on inspiration.
The sternum is drawn as far as possible from the spine.

These views demonstrate the external intercostals to be inspiratory; they are shortened in fig. VI. *b.*, and the internal intercostals to be expiratory. They are shortened in fig. VI. *a.* (§§ 22.25.26).

PLATE XXVI.

Fig. VII. (fig. XVI. *b.c.d.* Archives of the Royal Society). Muscles of respiration in the Porpoise (§§ 70-77).

Fig. VIII. (fig. XII. *b.* Archives of the Royal Society). Muscles of respiration in the Seal (§§ 55, &c. 62.67-69).

PLATE XXVII.

Fig. IX. (fig IX. *b.c.d.* Archives of the Royal Society). Muscles of respiration in the Calf (§§ 36, &c. 43).

Fig. X. (fig. XI. *b.c.d.* Archives of the Royal Society). Muscles of respiration in the Dog (§§ 55-69).

PLATE XXVIII.

Fig. XI. (fig. XII. *b.* Archives of the Royal Society). Muscles of respiration in the Rabbit (§§ 55, &c. 66.67).

Fig. XII. (fig. XIII. *b.* Archives of the Royal Society). Muscles of respiration in the Otter (§§ 55, &c. 67.68).

(Fig. X. *a.b.c.d.e.* Archives of the Royal Society). Muscles of respiration in the Ass (§§ 40-54).

(Fig. XV. *a.b.c.* Archives of the Royal Society). Muscles of respiration in the Monkey (§§ 55, &c. 78).

PLATE XXIX.

Illustrates the position of the ribs and the action of the external and internal intercostal muscles in expiration and inspiration in Man.

Fig. XIII. *a.b.* Are front views.

Fig. XIV. *a.b.* Side views; and

Fig. XV. *a.b.* Dorsal views in the young and the adult man.

In figs. XIII. *a.*, XIV. *a.*, XV. *a.*, the lungs are flaccid (expiration).

In figs. XIII. *b.*, XIV. *b.*, XV. *b.*, the lungs are distended (inspiration).

These views were taken by aid of a tracing frame (§ 4), and reduced by a pentagraph.

These figures demonstrate that during inspiration (§§ 1.4)

The five superior ribs, the thoracic set, approach each other.

The four inferior ribs, the diaphragmatic set, recede considerably from each other.

The sixth, seventh, and eighth ribs, the intermediate set, recede slightly from each other (§ 81).

The dorsal arch is deepened and shortened (§§ 80.81).

The external intercostals of the thoracic set of ribs are throughout inspiratory.

The external intercostals of the diaphragmatic set are, in front, expiratory; behind, inspiratory.

The external intercostals of the intermediate set are throughout inspiratory, being feebly so to the side (§ 85).

The eighth external intercostal is behind inspiratory; to the side, expiratory; and in front, acting from the fixed on the floating cartilage, inspiratory.

The internal intercostals are all expiratory behind.

The internal intercostals are inspiratory between the costal cartilages of the thoracic set of ribs.

The internal intercostals are inspiratory between the ribs of the thoracic set in front, where they approach each other during inspiration.

The internal intercostals between the diaphragmatic and intermediate sets of ribs, are throughout expiratory (§ 85).

The following additional drawings, illustrative of the paper, are deposited in the Archives of the Royal Society.

Fig. XIX. *a.b.* The female (§ 97),

Fig. XXI. *a.b.* and fig. XXII. *a.b.* The child (§ 99),

Fig. XXIII. *a.b.c.d.* The old man (§ 100),

Fig. XXIV. The foetus, and

Fig. XXV. The new-born infant (§ 98), are figures of the chest in pairs, illustrating the position of the ribs and the action of the intercostals in expiration and in inspiration.

Fig. VII. *a.b.* The Pig,

Fig. VIII. *a.b.* The Sheep,

Fig. X. *a.b.* The Ass, and

Fig. XI. *c.d.e.f.* The Dog, are figures of the chest in pairs, illustrating the position of the ribs and the action of the intercostal muscles in expiration (the lungs being flaccid) and in inspiration (the lungs being distended) (§§ 31–49, 56–61).

Fig. XXVI. Shows the blending of the transversales and sterno-costals in Man to form one muscle (§ 94).

Fig. XXVI. *a.* The pleural scalenus (in Man) (§ 84) (fig. XIII. *b.* 1 *a.*).